

Changing pattern of ovarian neoplasm in semi-urban population – A 3 year study from a teaching hospital in Tamil Nadu, India

Delphine T. Rose^{1,*}, Sudha VS²

^{1,2}Assistant Professor, Dept. of Obstetrics & Gynecology, Thanjavur Medical College, Thanjavur, Tamil Nadu

***Corresponding Author:**

Email: drdelphinerose@gmail.com

Abstract

Background: The female gonad 'OVARY' is multifaceted in its histology, embryology, steroidogenesis, and thus has the potential to acquire malignancy. Therefore ovarian neoplasms exhibit a wide variation in structure and biological behaviour. The main objective of our study is to find out the occurrence and distribution of various mass lesions in ovary in our population and to know its histopathological and clinical appearance.

Methods: This study was a retrospective and descriptive study done for a period of 3 years starting from the month of January 2013 to January 2016, at the Obstetrics and Gynaecology Department, Thanjavur Medical College, Tamil Nadu, India. All ovarian tumour cases diagnosed as neoplastic (benign, malignant and metastatic) were incorporated in the study.

Results: Out of 5728 gynaec admissions, 234 (4%) were found to have ovarian tumours. Of these 75.64% (177/234) were neoplastic and 24.36% (57/234) were non-neoplastic lesions. Among 177 neoplasms, the commonest histological pattern observed was epithelial tumours (73.45%). Of these, mucinous tumours (53.07%) were more frequent than serous type (46.92%). Mucinous cystadenoma (62.31%) was the commonest benign ovarian tumour and serous cystadenocarcinoma was the most frequently encountered malignant tumour (60.65%). Germ cell tumours (58%) were the commonest non-epithelial ovarian tumours.

Conclusion: Among the admissions, ovarian neoplasms were more in number than the non-neoplastic ones. Surface epithelial type was the predominant histological type observed and the germ cell tumours were the second commonest type. Mucinous cystadenoma and serous cystadenocarcinoma were the commonest benign and malignant ones respectively. The age of occurrence of malignant ovarian tumour has significantly come down and the predominant symptom was found to be mass abdomen.

Keywords: Ovarian tumour, Neoplasm, Epithelial tumour, Germ cell tumour, Mucinous cystadenoma

Introduction

After the uterus, in the female genital tract, the ovary is the second most common place for the occurrence of cancers. Ovarian cancer is called the 'silent killer' of the modern world because it is often diagnosed in late stages and hence the outcome is poor. Worldwide, 2,39,000 new cases of ovarian cancer and estimated deaths of 1,52,000 are recorded in 2014.⁽¹⁾ It is the second most common of all genital cancers and accounts for 10–15% of all gynaecological cancers in developing countries including India.⁽²⁾ Estimated new cases and deaths of ovarian cancer in the United States in 2015 is 21,290 and 14,180 with lifetime risk of about 1.33% and AAR (age-adjusted annual incidence rate) of 11.4 per 100,000 women.⁽³⁾ The risk of a woman developing cancer of the ovary in her lifetime is 1:70 to 1:100.² Indian cancer registry data in 2011 projects AAR of ovarian cancer from 10.7–11.2 per 100,000 in different parts of the country with the highest incidence in Kamrup urban district and Delhi registries.⁽⁴⁾ In spite of the advances made in its treatment strategies, cancer ovary still remains a challenge to the gynaecologists all over the world and continues to be the chief cause of death due to any gynaecological cancer. The reason being the ovaries are deep seated in the pelvis and are relatively inaccessible and has no known precursor lesions. This is why the various screening methods used

to diagnose ovarian cancer in early stages, are not very effective.⁽⁵⁾ Thus our present study was conducted to find out the significance of determining the clinicopathological type and how far it will influence the diagnosis, outcome and the appropriate treatment of ovarian tumours at our teaching hospital.

Method

In this retrospective study, all women with ovarian masses who underwent surgery, from January 2013 to January 2016 (3 years) were included. The study place was the Obstetrics and Gynaecology department, Thanjavur Medical College, Tamil Nadu, India. Patients who underwent medical treatment were expelled from the study. Relevant clinical history was obtained from the patients. Surgical specimens were sent to our pathology lab and histopathological examination was done. The diagnosed lesions were classified into neoplastic and non-neoplastic and were then analysed. The WHO (World Health Organization) classification of ovarian tumour was used for histological characterisation. Using descriptive statistics the collected data were analyzed and tabulated.

Results

Total number of gynaecological admissions during the study period was 5728. Total numbers of ovarian

tumours studied in this three year period were 234. True neoplastic lesions were 177 (75.64%) and the remaining (24.36%) were non- neoplastic (Fig. 1). Among the neoplasms, benign ovarian tumours were 106 (59.88%), malignant ovarian tumours were 55 (31.07%) and borderline tumours were 16 (9.03%) (Fig. 2). The commonest histological pattern observed in the study was epithelial type 130/177 (73.45%) (Fig. 3). Of the epithelial tumours, the mucinous type predominates and constitutes 53.07% (69/130), whereas the serous type was found to be 46.92% (61/130) (Fig. 4). Mucinous cystadenoma (62.31%) was the commonest benign ovarian tumour and serous cystadenocarcinoma (60.65%) was found to be the commonest malignant tumour (Fig. 5 & 6). Non epithelial tumours constitute 26.55% of all ovarian tumours. Germ cell tumours were the most frequently occurring non- epithelial type (27/47) 57.44% (Fig. 7). Benign mature cystic teratomas (88.88%) topped the list of germ cell tumours (Fig. 8). There were 3(11.11%) cases of malignant germ cell tumours, which included 1 malignant dysgerminoma, 1 endodermal sinus tumour and 1 immature teratoma. The number of sex cord stromal tumors were 10 (21.27%) with 8 cases of granulosa cell tumours and 2 cases of theca cell tumours, all benign. Others include seven cases of fibromas, (14.89%) all benign and 3 metastatic lesions (6%) from GIT (Fig. 9). Most of the benign epithelial tumours were observed in the age group of 20-40yr, while most of the malignant tumours cases were common in the elderly (40-60 yrs) age group (Fig. 10). Mass abdomen was found to be the commonest presenting symptom followed by pain abdomen (Table 1).

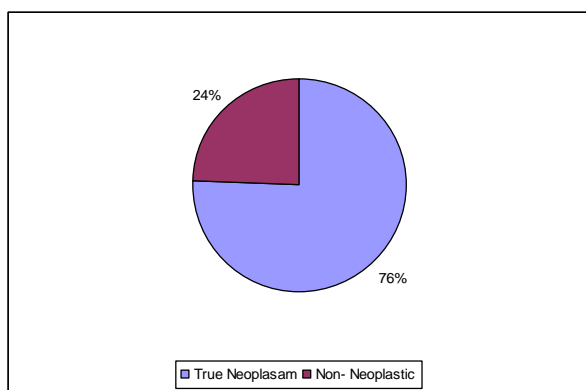


Fig. 1: Distribution of ovarian masses. Neoplasms & non neoplastic lesions

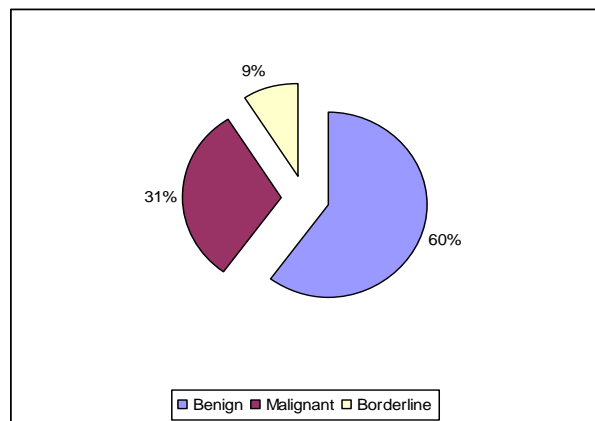


Fig. 2: Benign, malignant and borderline ovarian tumours

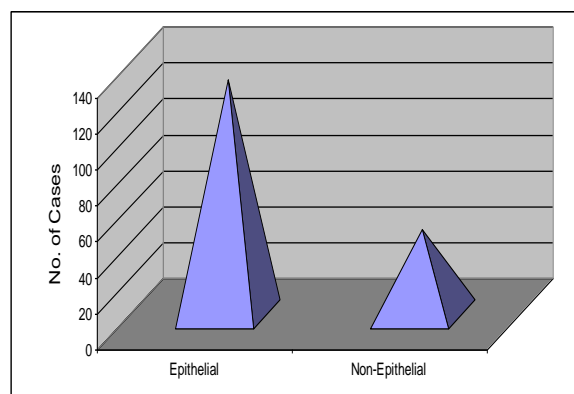


Fig. 3: Histopathological Pattern of Neoplastic Ovarian Masses

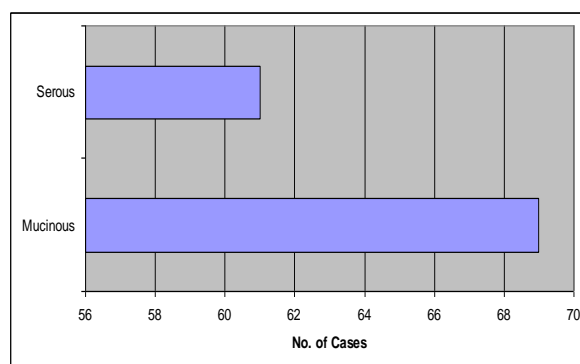


Fig. 4: Distribution of epithelial tumours

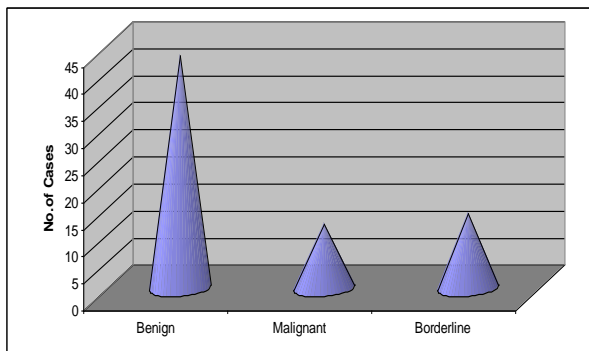


Fig. 5: Mucinous tumours

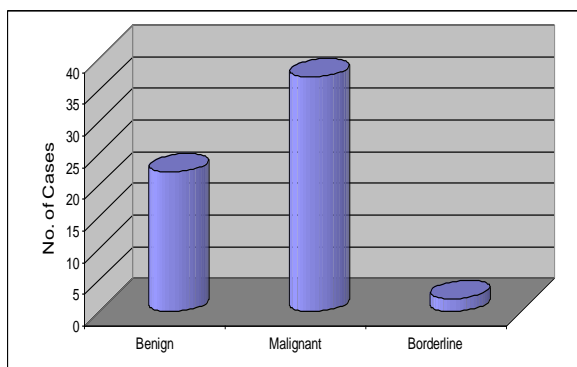


Fig. 6: Serous tumours

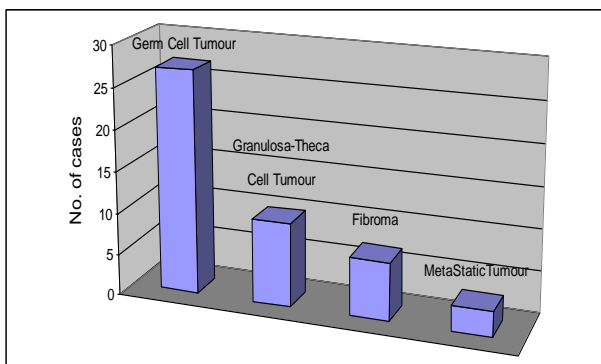


Fig. 7: Distribution of Non-epithelial tumours

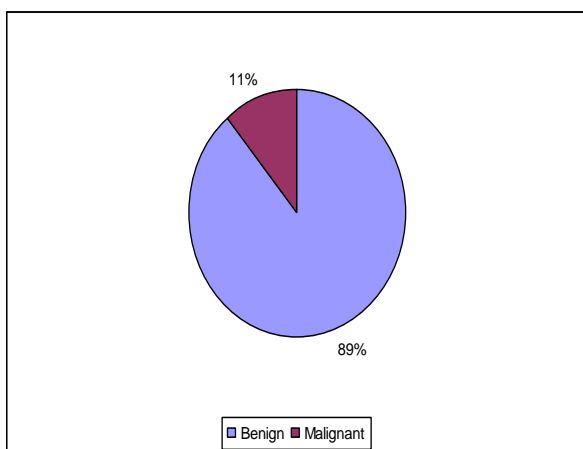


Fig. 8: Distribution of Germ cell tumours

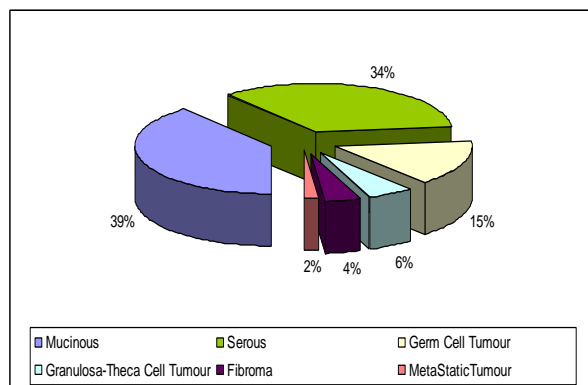


Fig. 9: Frequency of main histological types of ovarian tumours

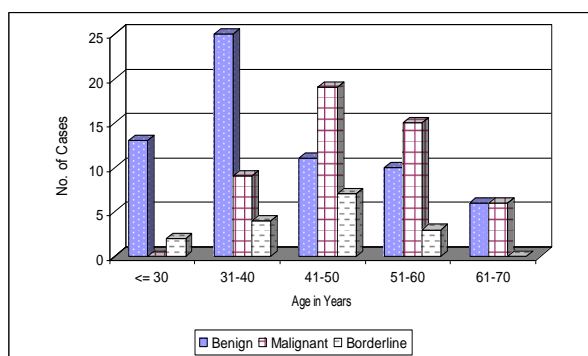


Fig. 10: Age-wise incidence of ovarian tumours

Table 1: Clinical presentation of ovarian tumours.

Clinical symptoms	No. of cases	Percentage
Mass abdomen	98	55.36%
Pain abdomen	47	26.55%
Dyspepsia	17	9.60%
Loss of appetite & weight	15	8.47%
Total	177	100%

Discussion

The epithelial ovarian tumours can be classified as benign, borderline or malignant based on the pattern of growth, predominant cell type, quantity of fibrous stroma and cellular atypia with invasiveness.⁽⁶⁾ Each of the major tumour types is named on the basis of a histologic pattern that resembles lower genital tract epithelium. In our study, the commonest histological type was found to be surface epithelial tumours which are consistent with Mondal SK, et al.⁽⁷⁾ Out of 177 cases, benign ovarian tumours were 106 (59.88%), malignant ovarian tumours were 55 (31.07%) and borderline tumours were 16 (9.03%). Gupta et al reported 72.9% benign, 4.1% borderline and 22.9% malignant tumours.⁽⁸⁾ The main portion of ovarian neoplasm in the study by Mondal SK, et al (2011) consists of benign tumours (63.1%), malignant (29.6%) and borderline tumours (7.3%).⁽⁷⁾ Whereas in another study, 80.3% of the total ovarian neoplasms were found

to be benign while malignant ovarian tumours comprised only 19.7%.⁽⁹⁾ This shows that the malignant and the borderline ovarian tumours are in the rise. In our study, mucinous cystadenomas were the commonest benign tumors (62.31%) which are in accordance with the study by Manivasakan et al,⁽¹⁰⁾ which showed a rising incidence of mucinous tumours. This changing trend carries significance as evidences state that mucinous type develops through a series, from a benign tumour through borderline tumour to invasive cancer and thus has a definite precursor lesion. Thus the borderline and invasive type of mucinous ovarian cancers can be prevented by surgical removal of these lesions. This can lead on to a considerable change in the mode of treatment in future. Of all the malignant tumours, serous cystadenocarcinoma comprised of 60.65% followed by 17.39% of mucinous cystadenocarcinoma which is comparable with the Jha et al.⁽¹¹⁾ Ethnic differences are found to be prevalent among ovarian tumours. In the study by Thanikasalam et al,⁽¹²⁾ it is shown that teratomas rank first among the people of Malaysia and China whereas serous tumours are the predominant benign ovarian tumours among Indians.

After the epithelial tumours, germ cell tumours were the next major group of tumours in the present study (27/177), majority of which comprised of benign cystic teratomas (24/27). Germ cell tumours were the second predominant type of tumours in the study (23.1%) by Mondal SK et al.⁽⁷⁾ However, in the African population there is higher incidence of germ cell tumours than the surface epithelial tumours.⁽⁹⁾ Sex cord-stromal tumours of the ovary, which account for around 5 to 8% of all ovarian malignancies, are tumours that are derived from the sex cords and the mesenchyme of the ovarian stroma.⁽¹³⁾

Our study reveals that the ovarian tumours can present in various ways. Some of the ovarian tumours may be asymptomatic and incidentally diagnosed during a routine ultrasound whereas others may present with mass and pain abdomen. In our study, mass abdomen 120 (67.79%) was the most common symptom followed by pain abdomen 47 (26.55%). Other symptoms were dyspepsia, weight loss and ascites, which were more common in malignant ovarian tumours.

These results were in contrast to a study carried out at by Rashid et al.⁽¹⁴⁾ in which abdominal pain was the commonest presenting complaint (59%) followed by abdominal mass/distension (37%). In another retrospective analysis by Jamal et al,⁽¹⁵⁾ the presenting symptoms were bleeding per vagina, followed by pain abdomen, pelvic mass and gastrointestinal symptoms.

Most of the benign tumours were observed in the age group of 20-40 yrs, while most of the malignant tumours were common in the elderly age group (40 - 60 yrs). Basic et al found ovarian cancers occurred more frequently in the similar age group.⁽¹⁶⁾

There are several limitations in our study that deserves comment. Our study is a single-centre retrospective study, the sample size is less and the study period is short. Therefore, the exact histological pattern, age distribution and the presenting feature of ovarian tumours need not be the same in all our Indian women. A large group multi-centric study is needed to confirm our results.

Conclusion

The main advantage of this study is that it gives a clear picture of the incidence of ovarian tumour and its histopathological type. Surface epithelial tumours are the commonest followed by germ cell tumours. Benign mucinous type predominates, there is a significant reduction in the mean age of occurrence of malignancy and the borderlines as well as the malignant ovarian tumours are showing a rising trend in our population.

Funding: No funding sources

Conflict of interest: None declared

Ethical approval: The study was approved by the Institutional Ethical Committee.

References

1. World Cancer Report 2014. World Health Organization 2014. Edited by Bernard W. Stewart and Christopher P. Wild Chapter 5.12 p 465.
2. Howkins & Bourne Shaw's Textbook of Gynaecology: 15th edition: Gynaecologic oncology: p422.
3. Cancer Facts & Figures 2015: American Cancer Society. Atlanta: American Cancer Society; 2015 Annual Report. 2015, p19. American Cancer Society, Inc., Surveillance Research www.cancer.org. A accessed May 2015.
4. Indian Council of Medical Research. Bangalore: National Cancer Registry Programme-2012. Consolidated Report of Hospital Based Cancer Registries 2009-2011. www.icmr.nic.in/nrcp/report. Accessed January 2015.
5. Kurman RJ, Ie-Ming S. The Origin and Pathogenesis of Epithelial Ovarian Cancer- A Proposed Unifying Theory. *Am J Surg Pathol Mar.* 2010;34(3):433-43.
6. Juan Rosai (2004), "Uterus-Cervix" Source: Rosai & Ackermann's Surgical Pathology, 9th Edition.
7. Mondal SK, Banyopadhyay R, Nag DR, Roychowdhury S, Mondal PK, Sinha SK. Histologic pattern, bilaterality and clinical evaluation of 957 ovarian neoplasms: A 10 year study in a tertiary hospital of eastern India. *J Can Res Ther* 2011;7:433-7.
8. Gupta N, Bisht D, Agarwal AK, Sharma VK. Retrospective and prospective study of ovarian tumours and tumour-like lesions. *Indian J Pathol Microbiol* 2007;50:525-7.
9. Onyiaorah IV, Anunobi CC, Banjo AA, Fatima AA, Nwankwo KC, Histopathological patterns of ovarian tumours seen in Lagos University Teaching Hospital: a ten year retrospective study. *Nig Q J Hosp Med.* 2011 Apr - Jun;21(2):114-8.
10. Manivasakan J, et al. A study of benign adnexal masses. *Int J Reprod Contracept Obstet Gynaecol.* 2012;1(1):12-6.

11. Jha R, Karki S. Histological pattern of ovarian tumors and their age distribution. *Nepal Med Coll J.* 2008;10:81-5.
12. Narula R, Arya A. Overview of benign and malignant tumours of female genital tract. *J Appl Pharm Sci.* 2013;3(01):140-9.
13. Young RH, Scully RE: Ovarian sex cord- stromal tumors: problems in differential diagnosis. *Pathol Annu*1988;23(Pt 1):273-296.
14. Rashid S, Sarwar G, Ali A. A clinicopathological Study of ovarian cancer. Departments of Radiotherapy and oncology Sir Ganga Ram Hospital and Mayo Hospital Lahore. *J Pak Med Assoc* 1998;36:117–25.
15. Jamal S, Quddusi H, Mehmood A. A Clinico Histopathological analysis of 110 ovarian tumours. *Pak J Med Sci* 1997;14:1923.
16. Basic E, Kozaric H, Kozaric M, Suko A. Ovarian-cancer incidence and surgical approach to treatment at clinic for Gynecology and Obstetrics of Clinical Center of University of Sarajevo in 2009. *Mater Sociomed,* 2010;22:101-4.