

## Efficacy of emergency internal iliac artery ligation in controlling post-partum hemorrhage

Prema Prabhudev<sup>1</sup>, Seema Chigateri<sup>2\*</sup>

<sup>1</sup>Professor & HOD, <sup>2</sup>PG Student, Dept. of Obstetrics & Gynecology, SSIMS & RC, Davanagere, Karnataka

**\*Corresponding Author:**

Email: seemachigateri@yahoo.com

### Abstract

Management of severe pelvic hemorrhage remains a major challenge in obstetrics as well as gynecology. Bilateral internal iliac artery ligation (BIAL) has been tried in this condition with varying success. The purpose of this study was to review the efficacy of this procedure in women with intractable pelvic hemorrhage.

**Materials and Method:** An observational study was conducted from 2014 May to 2015 November in the department of Obstetrics and Gynecology, SSIMS & RC Davanagere. During the study period, a total of thirteen emergency internal iliac artery ligation were performed as lifesaving procedure, along with either stepwise uterine devascularization or cesarean hysterectomy as and when required.

**Results:** Hemostasis was achieved successfully in ten patients. Of the three patients who required cesarean hysterectomy, one patient died due to multi organ dysfunction following hysterectomy. However, no complications related to BIAL were observed in any of the patient.

**Conclusion:** BIAL is found to be safe and effective procedure in our study, for treating life threatening obstetric hemorrhage. However, for unknown reasons the procedure is far less practiced than other radical options.

**Keywords:** Internal iliac artery ligation, Emergency, Pelvic hemorrhage.

**Manuscript Received: 23<sup>rd</sup> February, 2017**

**Manuscript Accept: 4<sup>th</sup> May, 2017**

### Introduction

Post partum hemorrhage has been the Achilles heel in the control of maternal mortality. Uterine atony is the commonest cause of life threatening obstetric hemorrhage.<sup>(1)</sup> Currently, failure of medical treatment is managed by uterine compression sutures, followed by stepwise uterine devascularization and arterial embolization. In patients not responding to these treatments, the traditional surgical treatment is to perform an emergency hysterectomy, eliminating any possibility of future fertility.

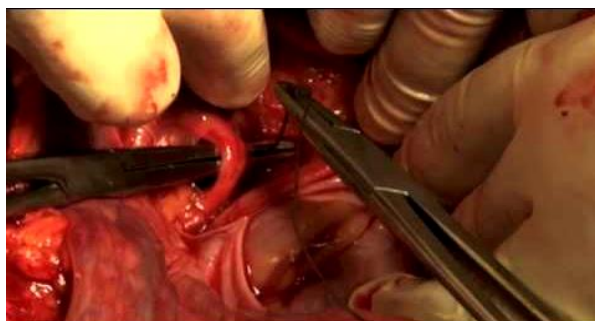
BIAL is an alternative lifesaving operation which preserves reproductive capacity. However, because of lack of expertise, only a few surgeons opt for this operation as opposed to emergency hysterectomy. American college of Obstetrics and Gynecology (ACOG), continues to advocate the use of BIAL in the management of intraoperative intractable hemorrhage during pelvic surgery or in cases of obstetric hemorrhage.<sup>(2)</sup> The rationale for this is based on the hemodynamic studies of Mengert and Burchell, way back in 1970's. They showed that BIAL reduced pelvic blood flow by 49% and pulse pressure by 85%. This drastic reduction in pressure results in attaining venous pressures in the arterial circuit, which in turn helps in promoting hemostasis.<sup>(3)</sup>

### Materials and Method

A total of thirteen emergency internal iliac ligations were performed between 2014 May to 2015

November in the department of Obstetrics and Gynaecology, SSIMS & RC, Davanagere, which is a tertiary centre for high risk Obstetrics. Their age, parity, duration of pregnancy, diagnosis, mode of delivery, cause of PPH, indication of BIAL, number of units of blood transfused, intra operative and post-operative complications and follow up were studied. Atonic or traumatic PPH, either at vaginal delivery or cesarean section, were managed with therapeutic BIAL. Prophylactic BIAL was also performed in one patient who was at risk (placenta previa, abruption) of developing PPH. Uterine massage and oxytocics were used as per active management protocol of third stage of labour.

BIAL was performed if these treatments could not control the bleeding. The ligation of internal iliac artery was done through intraperitoneal approach (Fig. 1). Of the total thirteen cases, seven cases with abruption underwent emergency cesarean section. All of them had atonic PPH, which failed to respond to uterotonics. Step wise uterine devascularization, was tried before proceeding with BIAL. Two cases of previous cesarean delivery in active labour had rupture uterus, which necessitated BIAL. However, due to intractable hemorrhage, cesarean hysterectomy was done in both the patients.



**Fig. 1: Ligation of anterior branch of internal iliac artery**

One woman, who delivered vaginally after outlet forceps application, had extensive vaginal and cervical tears. Initial exploration for tears and suturing was done. In view of hemodynamic instability, she underwent laparotomy and BIAL. Another patient with central placenta previa had cesarean section followed by a prophylactic BIAL in the absence of any significant uterine bleeding. A patient with severe abruption and IUFD underwent caesarean section. On the twelfth post-operative day, she had secondary PPH. Doppler studies showed pseudoaneurysm of the left uterine artery. Since the facility of uterine artery embolization was not available, BIAL was done and was successful in controlling the hemorrhage.

**Results**

Total of twelve BIAL was done for PPH and one prophylactic BIAL during the study period. Uterine atony (62%) was the common indication for therapeutic IIAL. Other indications were rupture uterus, central placenta previa and traumatic PPH. The mean age was 24years. Parity ranged from nulliparity to para 3. Cesarean hysterectomy was done in 3 cases following BIAL because of intractable hemorrhage. The procedure was successful in remaining ten cases done for therapeutic and prophylactic purpose. Of the total thirteen, one patient with ruptured uterus and IUD, who even underwent BIAL followed by cesarean hysterectomy died.

Remaining twelve cases after BIAL had no further bleeding in the post-operative period. None of the complications related to BIAL, like par-aesthesia over the gluteal area, necrosis of buttock and bladder atony, were observed. All twelve patients were discharged uneventfully and on postnatal follow up had no complications out of the procedure. Two of the twelve patients had even subsequent successful pregnancy. There was no evidence of fetal growth restriction or PPH in either of them.

**Table 1: Indications for BIAL n =13**

Indication	Number of women (%)
Placenta abruption	8
Genital tract injury	1
Placenta previa	1
Rupture uterus	2
Secondary PPH	1
Total	13

**Table 2: Hysterectomy in women undergoing IIAL for uterine hemorrhage**

Indication	Total number of women	Hysterectomy carried out(n)	Uterine salvage rate (%)
Placental abruption	8	0	100
Genital tract injury	1	0	100
Placenta previa	1	0	100
Rupture uterus	2	2	0
Secondary PPH	1	0	100

**Discussion**

BIAL is an effective emergency lifesaving procedure to control obstetric and gynaecological haemorrhage.

Postpartum haemorrhage management can be life threatening.

From time immemorial, efforts are evident in curbing the PPH. Way back in 1893, Sir Howard Kelly was the first person to do BIAL. Later on, Mengret and Burchel popularized the procedure. The conversion in arterial pressure into venous pressure, facilitating stasis, is the basic principle of BIAL. Pulse pressure is decreased up to 77% by unilateral ligation of internal iliac artery and up to 85% by BIAL. Reduction in the blood pressure will cause blood to clot from the site of damaged vessels without any compromise in blood circulation to pelvis. There exists, extensive collaterals between aorta and the femoral artery including lumbar, iliolumbar, middle sacral, lateral sacral, superior and middle haemorrhoidal and gluteal arteries. Hence, as early as about 45 to 60 minutes after ligation, collateral circulation becomes evident.

In a multi-center retrospective study from Turkey, out of 53 patients who underwent BIAL for severe PPH, only in 17 (32.0%) cases Uterus was preserved. Twenty six (49.1%) patients during the postoperative period developed coagulopathy.<sup>(4)</sup> Hence, this may account for the low success rate of BIAL in this study when compared to other studies.

In a prospective study from Egypt, Refaie and others, 51 pregnant women with adherent Placenta (both accreta and increta) were evaluated. After the fetal delivery and before placental extraction, all

patients underwent prophylactic BIAL. Satisfactory hemostasis was achieved in 82.6% of patients. However, 29.6% patients with placenta increta further underwent hysterectomy in view of refractory bleeding.<sup>(5)</sup>

In a prospective study from India, benefits and risks associated with BIAL in 64 women were studied. Women with Placenta previa (21.8%), constituted the major group. BIAL had 96.87% efficacy. Four out of sixty four women died following the complications of bleeding. However, there were no procedure related complications. The patients were followed up at 6 weeks and 6 months. Flow in distal part of ligated internal iliac arteries could be detected in women out of 60 after 6 months of ligation of internal iliac arteries.<sup>(6)</sup>

Only few other studies do mention on recanalization. There is also a possible risk of severe retroperitoneal hemorrhage from recanalized vessels with turbulent flow and abnormal hemodynamics.<sup>(7)</sup>

In the largest reported series on pregnancy following hypogastric artery ligation, seventeen patients had 21 pregnancies over the study period of 13 years. Thirteen term deliveries, three miscarriages, two ectopic pregnancies; three patients had a PPH and were managed medically.<sup>(8)</sup>

In the guidelines on management of PPH, by WHO, Twenty-one case series and 13 case reports, with 532 women were considered for studying the outcome of BIAL. The reported success in prevention of hysterectomy varied from 62% to 100%. The guideline also reviewed evidence on arterial embolization. Eighteen case series and 15 case reports, in a total of 340 women were considered for evaluation. The success in avoiding hysterectomy varied from 82% to 100%.<sup>(9)</sup>

In cases with intractable PPH, before proceeding to invasive procedures, the guideline recommends either BIAL (with a strong strength of recommendation) or arterial embolization, where facilities are available. (With a weak strength of recommendation). However, they did acknowledge that, the level of competence of the surgeon, available facilities will decide on the selection of sequence of interventions.<sup>(9)</sup>

The Agency for Healthcare Research and Quality (AHRQ) reviewed the literature addressing PPH. The success of uterine sparing measures in life threatening PPH had a large variation from 36% to 98%. The literatures were considered to have poor quality and therefore, comparing between the studies is not feasible. Most studies were retrospective and only few prospective studies. Hence, they recommend further research into all interventions in the management of PPH.<sup>(10)</sup>

Recently there are some trials published on selective arterial occlusion or UAE (Uterine artery embolization) versus BIAL.

An RCT compared intraoperative internal iliac artery ligation versus balloon occlusion. In the balloon

occlusion group with 50 patients, the catheters were secured with their inflatable part within the distal common iliac and the proximal portion of the internal iliac artery. Then the patients were shifted for planned delivery. The other group also consisted of 50 patients. All these patients underwent prophylactic BIAL. In the balloon group, hemostasis was achieved in 33 (66%) out of 50 patients. In the BIAL group, 29(58%) out of 50 achieved it. Additional surgical interference was needed in 12 and 15 patients in the balloon group and BIAL group respectively. Hysterectomy was done in five and six patients in the balloon group and BIAL group respectively. Blood loss and hospital stay was slightly more in BIAL group.<sup>(11)</sup> However, the UAE group did expose the fetuses to radiation.

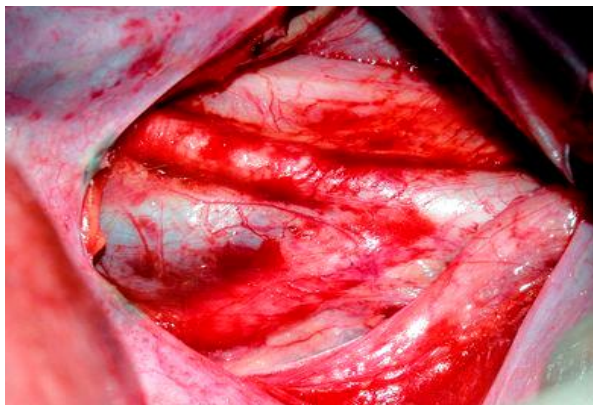
A randomized control trial compared uterine artery embolization versus serial devascularization. Eleven in UAE group and twelve in serial devascularization group, a total of 23 women were enrolled. In the serial devascularization group, initially bilateral uterine artery ligation was done and if failed, B-lych sutures were applied. If these failed, then the patients underwent BIAL. In the UAE group, 9 patients were successfully treated and 2 progressed to need hysterectomy. In the serial devascularization group, 9 patients were successfully treated and 3 progressed to hysterectomy. Both the groups had similar complications rate.<sup>(12)</sup>

Cairo University is conducting a trial in women with pre-operative diagnosis of placenta percreta. The trial aims to compare BIAL versus hysterectomy. The amount of blood loss, complications, morbidity and mortality would be compared between the two groups. It is expected to enroll 50 patients. The study is still cited to be recruiting.<sup>(13)</sup>

Both angio-embolization and BIAL have their own pros and cons. Other than the Interventional radiology facilities, angio-embolization can take time of one to three hours to complete; it can fail to control the bleeding in 10% of cases. If the patient is unstable, transferring the patient from operating room to the interventional suite is not advisable. Complications of angiography, pelvic infection and maternal thromboembolic events, are all possible adverse incidents that can occur. Catheter related complications are reported in as high as 7% of patients.<sup>(14)</sup> On the other hand, UAE can have some advantages. UAE purportedly initiates uterine contractions which lead to liberation of procoagulant factors into circulation and hence offsets the DIC and bleeding diathesis.<sup>(15)</sup> However, studies need to prove this yet.

BIAL has got its own difficulties. It is a very challenging technique even for an experienced surgeon. Accidental ligation of external iliac artery can lead to loss of ipsilateral limb. Any Injury to the iliac vein, which lies just medial to the artery (Fig. 2), can lead to life threatening exsanguination. The large uterus, obese patient, continued pelvic hemorrhage adds on to the woes of the surgeon. In conditions like placenta

percreta, benefit of BIAL may be negated by the extensive collaterals. However, BIAL saves time, requires no expensive facilities as for embolization. One can try modifying the risk of BIAL by using alternative methods of arterial occlusion. Arterial clamps or tapes, may be more easily applied, would be reversible (if needed), would also carry a lesser chance of injury or delayed possibility of pseudoaneurysm.



**Fig. 2: Photograph showing demonstrable vulnerability of internal iliac vein, internal iliac artery in close proximity**

It is surprising to see, even though PPH is common, reported series have a low number of participants. Most studies have their own variations like serial devascularization, directly going for BIAL. The amount of blood loss, units of blood products used, secondary infection, associated sepsis and multi organ failure, disseminated intravascular coagulation all may vary the outcome. Quantification and severity of PPH, associated co-morbidities, parity, availability of the facilities and expertise, patient wishes; all may have an influence on the decision of choosing one option over the other. This makes comparison between the studies difficult.

As also seen with the above 2 trials and the ongoing trial, the study population is again small. A well planned, multi centric study with a large matched population, may bring out more clarity to the ongoing controversy between angio-embolization versus BIAL, in their superiority. With improved antenatal care and increased availability of diagnostic facilities, patients with risk of PPH may be referred to high risk obstetrics centre, well in advance.

## Conclusion

In the current era of vascular interventions, intractable PPH is managed in with angio embolization of the uterine artery. However, the facility and expertise may not be available in many hospitals. Even in centers where uterine artery embolization is available, stringent, controlled studies comparing the efficacy, cost benefit ratio of uterine artery embolization versus BIAL are needed.

Obstetrician, who is managing the aforesaid complication, can perform BIAL, provided appropriately trained for it. Lack of Knowledge or expertise will deny the option of future pregnancies to these patients, as many will be treated with radical options like hysterectomy. Postgraduate training programme should include orientation of trainees to this life saving procedure. Mannequin models or simulators can be developed to train them.

Although BIAL is found to be safe and effective procedure in our study for treating life threatening obstetric hemorrhage, further large controlled trails are required. It should be the operation of choice to control severe bleeding in young woman of low parity. We believe there is an urgent need to train and familiarize the younger generation of obstetricians to perform BIAL. A tertiary referral center should have all the surgeons trained for this procedure, as it is inexpensive, yet effective.

## References

1. WHO analysis of causes of maternal death: A systematic review. *Lancet*. 2006;367:1066-1074.
2. American College of Obstetricians and Gynecologist. Haemorrhagic shock. ACOG Educational Bulletin 1997; No. 235.
3. Burchell RC. Physiology of internal iliac artery ligation. *J ObstetGynaec Brit Cwlth*. 1968;75:642-651.
4. Evsen MS, Sak ME, Soydine HE et al. Internal iliac artery ligation for severe postpartum hemorrhage. *Ginekol Pol*. 2012 Sep;83(9):665-8.
5. Waleed Refaie, Muhammad Fawzy, Ahmed Shabana. Prophylactic bilateral internal iliac artery ligation for management of low-lying placenta accreta: a prospective study. *Tanta Medical Journal* 2014,42(4):146-150.
6. Singh A, Kishore R, Saxena SS. Ligating Internal Iliac Artery: Success beyond Hesitation. *J Obstet Gynaecol India*. 2016 Oct; 66(Suppl 1):235-41.
7. Raba G. Unilateral recanalisation of hypogastric artery after ligation for postpartum haemorrhage treatment. *Wideochir Inne Tech Maloinwazyjne*. 2014 Jun;9(2):289-91.
8. J. Nizard L. Barrinque R. Frydman H. Fernandez. Fertility and pregnancy outcomes following hypogastric artery ligation for severe post-partum haemorrhage. *Hum Reprod* (2003);18(4):844-848.
9. WHO Guidelines Approved by the Guidelines Review Committee. WHO Guidelines for the Management of Postpartum Haemorrhage and Retained Placenta. 2009, Geneva.
10. Likis FE, Sathe NA, Morgans AK et al. Management of Postpartum Hemorrhage. Comparative Effectiveness Review No. 151. (Prepared by the Vanderbilt Evidence-based Practice Center under Contract No. 290-2012-00009-I.) AHRQ Publication No. 15-EHC013-EF. Rockville, MD: Agency for Healthcare Research and Quality; April 2015.
11. El-sayed MLM, El-huseiny AM, Ahmed MA, Saber S. Intraoperative internal iliac artery balloon occlusion versus ligation in cases of placenta previa accreta: A randomized trial. *Edorium J Gynecol Obstet* 2016;2:34-40.
12. Farouk O, Elbasuony W, Elbohouty A. Uterine artery embolization versus surgical management in primary

- atonic postpartum hemorrhage: A randomized clinical trial. *The Egyptian Journal of Radiology and Nuclear Medicine* (2016) 47, 817–823.
13. ClinicalTrials.gov [Internet]. Bethesda (MD): National Library of Medicine (US). 2000 Feb 29 - . Identifier NCT02728232, Internal Iliac Artery Ligation and Placenta Percreta; 2016 Mar 31 [cited 2017 Feb 28]; [about 4 screens]. Available from: <https://clinicaltrials.gov/ct2/show/NCT02728232>.
  14. Hansch E, Chitkara U, McAlpine J, El-Sayed Y, Dake MD, Razavi MK. Pelvic arterial embolization for control of obstetric hemorrhage: A five-year experience. *Am J Obstet Gynecol* 1999 Jun; 180(6 Pt 1):1454–60.
  15. Pelage JP, Le Dref O, Mateo J, et al. Life-threatening primary postpartum hemorrhage: treatment with emergency selective arterial embolization. *Radiology* 1998;208:359–62.