

Spontaneous Uterine Rupture of an Unscarred Uterus before Labour- A case report

Annapoorna Yalla^{1*}, Sarojini Vaddadi²

¹Assistant Professor, ²HOD, Dept. of Obstetrics & Gynecology, GSL Medical College & General Hospital, Rajamahendravaram, Andhra Pradesh

***Corresponding Author:**

Email: drsannapoorna@gmail.com

Abstract

Uterine rupture is a rare but a life threatening condition in pregnancy. This is usually reported in scarred uterus, multigravid women and in laboring women. We are reporting a unique case of rupture of an unscarred uterus in a primigravid woman with review of literature.

Keywords: Spontaneous uterine rupture, Annapoorna Sontyana, Unscarred uterus

Manuscript Received: 1st April, 2017

Manuscript Accept: 13th May, 2017

Introduction

Uterine rupture is a rare but a life threatening condition in pregnancy and one of the major causes of maternal mortality. Most common risk factor is previous caesarian section in modern obstetrics. Other risk factors include uterine abnormalities, grand multiparity, fetal macrosomia, cephalopelvic disproportion, fetal malpresentation, congenital uterine anomalies, labor augmentation with misoprostol or oxytocin, application of fundal pressure, placenta accreta, history of gestational trophoblastic disease, seatbelt accidents, and myometrial damage from prior instrumentation such as in abortion with repeated curettage or hysteroscopic metroplasty.⁽¹⁻⁶⁾ Rarely intrauterine manipulations such as internal podalic version and breech extraction are also known risk factors. The incidence after myomectomy is extremely low.⁽²⁾

Case Report

A 35 yr old primi, unbooked case, 34 weeks gestation presented to casualty with Complaints of diffuse pain in lower abdomen and breathlessness since past 24 hrs. She was not able to perceive fetal movements from past 24 hrs. No history of trauma, fall, leaking or bleeding per vaginum. No history of previous surgeries, abortions, known uterine malformations or tuberculosis. She denies any drug intake. Her antenatal period was uncomplicated with 4 checkups at another hospital and normal scan and

bloods. At admission she was pale with tachycardia (122bpm) tachypnoea (40/min) and blood pressure 130/80 mm hg. On obstetric examination abdomen was distended with tenderness all over abdomen, uterine contour was not present, fetal parts could not be felt and a fetal head was palpated in left iliac fossa separately. Fetal heart sounds could not be auscultated. On vaginal examination cervix was short, firm & taken up, external os was closed. Uterine rupture was suspected and maternal resuscitation started by volume expanders and blood made available. Foleys was placed and urine draining was clear. An ultrasound was done which confirmed intrauterine death with fetus partially outside uterus and mild hemoperitoneum. An MRI was done which showed 5 cm rupture at fundus with placenta and fetus in the abdominal cavity and mild hemoperitoneum[Fig. 1]. Laboratory investigations showed hemoglobin 8.7gm%, PCV-28, TC, DC, ESR-normal BT 3' 30 sec, CT 5'30. RBS- 125mg/dl, BU 21 mg/dl. Sr creatinine 0.9 mg/dl. She was taken up for emergency laparotomy in which 600 ml of blood and clots seen in peritoneal cavity. A dead fetus weighing 2.2 kgs along with placenta was removed from abdominal cavity. A rent of 8 cm seen in the fundus extending into posterior uterine wall more on left side [Fig. 2] which was repaired in three layers with vicryl. She recovered well with a blood transfusion postoperatively. Sutures were removed on 7th postoperative day.

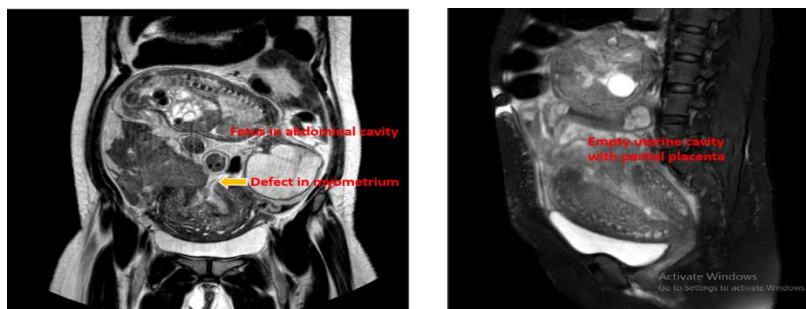


Fig. 1: MRI showing posterior wall rupture of uterus with fetus in the abdominal cavity. The second image shows partial attachment of placenta to fundus with empty uterine cavity

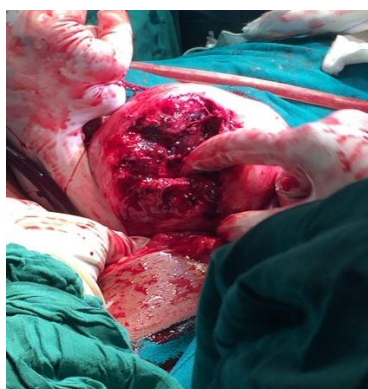

Fig. 2: Intraoperative picture showing irregular rupture of posterior uterine wall

Discussion

Uterine rupture is tearing or giving way of uterine wall during pregnancy or in labour. Uterine rupture is an important cause of maternal mortality, accounting for as many as 9.3% of maternal deaths in India.⁽⁷⁾

The most common risk factor for having a rupture uterus is presence of a scarred uterus. Among the cases with history of prior uterine surgery, the vast majority of patients had prior low transverse cesarean section (84.8%).

In women with a previous caesarean section, around 1% of had a ruptured uterus.⁽⁸⁾ The incidence of uterine perforation associated with abortion by suction curettage is reported to be around 0.08–0.17%.^(9,10,11) Uterine perforation in operative hysteroscopy is an uncommon complication, with an incidence of 1.5%.^(12,13)

Halvorson et al. (1993) documented the first case of spontaneous uterine rupture during pregnancy following hysteroscopic metroplasty complicated by uterine perforation.⁽¹⁴⁾

Although most uterine ruptures occur in women with prior scarred uterus, rupture of the nulliparous unscarred uterus is also possible. Spontaneous uterine rupture is an extremely rare event, estimated to occur in one of 8,000 to one of 15,000 deliveries.⁽¹⁵⁾

Spontaneous rupture is most commonly seen in multigravida women, women with obstructed labour, malpresentations, malpositions, macrosomic and

anamalous baby, labour induction [esp with prostaglandins], multiple pregnancy, history of invasive mole, undue fundal pressure, internal podalic version, assisted breech delivery, abdominal trauma, gun shot wounds, instrumental deliveries and malformed uterus.

Congenital uterine malformations complicate 1:594 pregnancies.⁽¹⁶⁾ Importantly, the walls of congenitally abnormal uteri are thinner than for normal uteri.^(17,18) Moreover, their myometrium tends to diminish in thickness as gestation advances and can be inconsistent over different aspects of the uterus. Furthermore, additional wall thinning can occur as a result of uterine contractions.

Complete rupture involves the entire uterine wall and results in a direct connection between the peritoneal space and the uterine cavity. In incomplete rupture vesicouterine peritoneum is intact.

In 50%, uterine rupture occurs at the previous lower segment cesarean section (LSCS) scar.^(19,20) Rupture of LSCS scar most often takes place when the women are allowed to labor.

Our case did not have any of the above said risk factors. So, there should be a high index of suspicion and ultrasound support to achieve diagnosis. Uterine rupture has various clinical presentations, including maternal shock due to sudden bleeding, abdominal pain over the site of uterine rupture, or changes in fetal heart rate due to an interruption of blood supply to the fetus.

Changes in the fetal heart rate may vary depending on whether the tear involves the site of placental attachment. If the placental site is involved, signs of fetal distress may be observed.⁽²¹⁾ Other potential clinical manifestations include maternal tachycardia, hypotension ranging from subtle to severe (hypovolemic shock), cessation of uterine contractions, loss of station of the fetal presenting part, uterine tenderness, and change in uterine shape. Intuitively, loss of integrity of the uterine wall should be associated with a reduction in intrauterine pressure, but case series where an intrauterine pressure catheter was in place at the time of rupture have generally not observed pressure changes significantly different from laboring patients without rupture.^(22,23)

Spontaneous rupture of a uterus should be included in the differential diagnosis of any pregnant woman

with previous uterine surgery, unexplained abdominal pain, and fetal heart rate anomalies. The other differential diagnosis are abruptio placenta, subhepatic hematoma with or without liver rupture, splenic rupture, rupture of the broad ligament, and rupture of a uterine vein.

We have successfully repaired the rupture site. However, the decision to perform uterine repair or hysterectomy incases of uterine rupture is influenced by the parity, number of living children, extent of uterine rupture, condition of the tissues, and the general condition of the patient. Repair of the uterine rupture is a logical approach and should be performed in women with scar rupture, and in those with a linear tear.

There are only but a few cases of uterine rupture in a primigravid non laboring women reported and the cause remains unsolved. Any inherent defect in the uterine musculature is thought to be the reason and further evidence should be present to solve the dilemma.

References

1. Sakr R, Berkane N, Barranger E et al: Unscarred uterine rupture: case report and literature review. *Clin Exp Obst Gyn*, 2007;34:109–92.
2. Golan D, Aharoni A, Gonen R et al: Early spontaneous rupture of the post myomectomy gravid uterus. *Int J Gynecol Obstet*, 1990;31:167–70.
3. Catanzarite V, Cousins L, Dowling D, Daneshmand S: Oxytocin-associated rupture of an unscarred uterus in a primigravida. *Obstet Gynecol*, 2006;108:723–25.
4. Rahman J, Al-Sibai MH, Rahman MS: Rupture of uterus in labor. *Acta Obstet Gynecol Scand*, 1985;64:311.
5. Langton J, Fishwick K, Kumar B, Nwosu EC: Spontaneous rupture of an unscarred gravid uterus at 32 weeks gestation. *Hum Reprod*, 1997;12:2066.
6. Chang C-Y, Chou S-Y, Chu I-L et al: Silent uterine rupture in an unscarred uterus. *Taiwanese J Obstet Gynecol*, 2006;45:250.
7. Rajaram P, Agarwal A, Swain S. Determinants of maternal mortality: a hospital based study from South India. *Indian J Matern Child Health* 1995;6(1):7–10.
8. (WHO systematic review of maternal mortality and morbidity: the prevalence of uterine rupture *BJOG: an International Journal of Obstetrics and Gynaecology* September 2005, Vol. 112, pp. 1221–1228).
9. Cheng P-J, Chueh H-Y, Soong Y-K: Sonographic diagnosis of a uterine defect in a pregnancy at 6 weeks' gestation with a history of curettage. *Ultrasound Obstet Gynecol*, 2003;21:501–3.
10. Chen LH, Lai SF, Lee WH, Leong NK: Uterine perforation during elective first trimester abortion: a 13-year review. *Singapore Med J*, 1995;36:63–67.
11. Lindall G, Flam F: Management of uterine perforation in connection with legal abortions. *Acta Obstet Gynecol Scand*, 1995;74:373–75.
12. Peterson HB, Hulka JF, Philipps JM: American Association of Gynecologic Laparoscopists' 1988 membership survey on operative hysteroscopy. *J Reprod Med*, 1990;35:590–91.
13. Conturso R, Redaelli L, Pasini A, Tenore A: Spontaneous uterine rupture with amniotic sac protrusion at 28 weeks subsequent to previous hysteroscopic metroplasty. *Eur J Obstet Gynecol Reprod Biol*, 2003;107:98–100.
14. Halvorson LM, Aserkoff RD, Oskowitz SP: Spontaneous uterine rupture after hysteroscopic metroplasty with uterine perforation. A case report. *J Reprod Med*, 1993;38:236–38.
15. Miller DA, Goodwin TM, Gherman RB, Paul RH. Intrapartum rupture of the unscarred uterus. *Obstet Gynecol* 1997;89:671-3.
16. Nahum GG. Uterine anomalies: how common are they and what is their distribution among subtypes? *J Reprod Med* 1998;43:877–87.
17. Schauffler GC. Double uterus with pregnancy. *JAMA* 1941;117:1516–20.
18. Nahum GG. Rudimentary uterine horn pregnancy: a case report on surviving twins delivered eight days apart. *J Reprod Med* 1997;42:525–32.
19. Ofir K, Sheiner E, Levy A et al. Uterine rupture: Risk factors and pregnancy outcome, *Am J Obstet Gynecol* 2003;189:1042-6.
20. Ibha K, Poonam G, Sehgal A et al. Rupture of the gravid uterus: Experience at an urban medical center in Northern India. *J Obstet Gynecol India* 2003;53:558-62.
21. Kerimis P, Zolti M, Sinwany G et al: Uterine rupture after hysteroscopic resection of uterine septum. *Fert Steril*, 2002;77:618–20.
22. Rodriguez MH, Masaki DI, Phelan JP, Diaz FG. Uterine rupture: are intrauterine pressure catheters useful in the diagnosis? *American journal of obstetrics and gynecology*. 1989 Sep;161(3):666-9.
23. Ridgeway JJ, Weyrich DL, Benedetti TJ. Fetal heart rate changes associated with uterine rupture. *Obstetrics and gynecology*. 2004 Mar;103(3):506-12.