

Comparative study of P53 expression between inflammatory and mild dysplasia of cervical epithelium

Divya B¹, Ashwini Nayak U^{2,*}, Sridhar Honnappa³

¹PG Student, ²Associate Professor, Dept. of Obstetrics & Gynaecology, ³Associate Professor, Dept. of Pathology, M.S. Ramaiah Medical College & Teaching Hospital, Bangalore

***Corresponding Author:**

Email: ms.drashwini@rediffmail.com

Abstract

Introduction: Cervical cancer is the most common cancer among females in the developing countries. HPV virus plays vital role in cervical carcinogenesis. p53 inactivation plays a key role in etiology of cervical cancer. Various screening methodologies have been developed for early detection of cervical carcinoma. Recently many biomarkers have been used for diagnostic and prognostic purpose in carcinoma cervix. p53 expression can be used as a marker for the aggressive behaviour of tumor.

Objectives: To compare the expression of p53 in inflammatory lesions of cervix and mild cervical dysplasia

Materials and Method: Patients coming to the institution who are undergoing biopsy for abnormal cytology/colposcopy during the study period of July 2015 to July 2016 are included in the study. Total of 20 patients were studied. Immunohistochemistry was used to study the p53 expression in inflammatory cervicitis and mild dysplasia of cervical epithelium

Results: Out of 20 patients studied, p53 expression is found to be significant in CIN1 lesions (p value- 0.000). p53 positivity was found in CIN 1 in 38.5%(5/7) cases and negative in all cases of non- specific cervicitis

Conclusion: In the present study, p53 expression was absent in inflammatory lesions and positivity was found in CIN1 lesions. This helps in identifying the subset of dysplastic lesions which need to be followed up more vigilantly to prevent their development into cancers. This could also be used as a backup for histopathology and also in cytology when there is ambiguity in knowing whether there is dysplasia or not.

Keywords: p53, Immunohistochemistry, Cervical intraepithelial neoplasia(CIN).

Received: 22nd June, 2017

Accepted: 6th October, 2017

Introduction

Cervical cancer is the most common gynaecological cancer among females in the developing countries. With 5,28,000 new cases every year, cervical cancer is the fourth most common cancer affecting women worldwide after breast, colorectal and lung cancer.⁽¹⁾ It is fourth most common cause of cancer death (2,66,000 in 2012) in women worldwide and India accounts for one fifth world's burden of cancer cervix. It is the 2nd most common cancer in India.⁽²⁾ In India, 1,23,000 new cases and 67,000 deaths documented because of cervical cancer in 2012 (Globacan, 2015).

HPV virus plays vital role in etiology of majority of cervical cancers. HPV virus especially high risk varieties like HPV 16 & 18 first integrate with host cell genome and then express two proteins E6 & E7. E6 inhibits the activity of p53 which is a protein which controls DNA reparative mechanism, causes apoptosis and G1 arrest in case of cellular stress. As a result of loss of p53, there is uninhibited proliferation of cells resulting in development of malignant cells. p53 inactivation thus plays a key role in cervical carcinogenesis. There are primary and secondary biomarkers in cervical carcinoma. The primary marker being HPV DNA and secondary markers like p53, c-fos, p50, fra 1, p16, notch 1, rb and telomerase. Studies have shown that p53 can be used as a prognostic factor

for the aggressive behaviour of the tumor.⁽³⁾ Hence p53 protein expression in cervical epithelium maybe a useful marker contributing information complementary to morphology and prognosis.⁽³⁾

Studies have shown p53 expression increases with CIN lesions and this fact can be used in clinical practice to identify those patients who require more surveillance. In India only few studies are available in relation to p53 expression. This study will advance our understanding of carcinogenesis of cancer cervix

Materials and Method

Patients coming to M.S. Ramaiah Hospitals who are undergoing biopsy for abnormal cytology/colposcopy and cervical growth during the study period of July 2015 to July 2016 are included in the study. Total of 20 patients were studied. Out of 20 patients studied 13 of CIN 1 and 7 non-specific cervicitis. Clinical data was obtained in each case regarding name, age, history of present illness, personal history and any other associated complaints. Hysterectomy specimens were also considered for the study. Biopsy was processed and stained with Hematoxylin and Eosin staining. The sections were examined for nonspecific cervicitis and CIN1 and studied for p53 expression. The Horseradish peroxidase method was used. The positivity was considered if more than 10% of nuclei are stained. All the 20 cases were subjected to IHC

study for p53. The polymer based IHC kit of Pathn Situ RTU was used. All the quantitative variables such as age was analysed & described in terms of mean and standard deviation. All qualitative variables were expressed in terms of percentages. The data were analysed and processed by the SPSS program, version 20. For statistical analysis both the non-parametric tests of pearson's Chi-square X2 and Fishers exact test were used. $p < 0.05$ values were considered statistically significant.

Result

In the present study, total of 20 patients were studied in department of obstetrics and gynaecology during the study period from July 2015 to July 2016. Out of 20 cases, 13 cases were CIN 1 and 7 cases were of nonspecific cervicitis. In the present study, age distribution of the patients ranging from 25 years to 80 years. Mean age was 45.41 ± 10.6 years. The mean age of the patients with nonspecific cervicitis was 40.86 ± 11.27 years while that of CIN1 was 46.23 ± 13.26 years. (Table 1) In the present study, 38.5 % cases (5 out of 13 cases) of CIN lesions showed p53 stain positivity (Table 2). When location of p53 staining of the squamous epithelial lesions of cervix was studied- 20% of the surface layer, 60% of the basal layer, 20% of basal and intermediate layer was stained. (Table 3) Immunoreactivity for p53 protein showing mild nuclear staining(+1) in basal epithelial cell of CIN1 is depicted in Fig. 1. p53 staining was scored in cervical epithelium of CIN1 was score 1-80%, score 3 was 20%. (Table 4)

Table 1: Distribution of the cases according to the mean age of the patients

Different lesions	Mean age \pm standard deviation
NSC	40.86 ± 11.27
CIN1	46.23 ± 13.26

Table 2: p53 Positivity in Various Lesions

HPE	No of Cases	P53 Positivity	Percentage (p value-0.0001)
NSC	7	0	0
CIN1	13	5	38.5%

Table 3: Location of p53 staining in the squamous epithelial lesions of cervix

Location	HPE
	CIN1
Surface layer	20.0%
Basal layer	60.0%
Basal & intermediate	20.0%

Table 4: Scoring of p53 staining in cervical epithelium of CIN1

P53 scoring	HPE
	CIN1
Score 1	80.0%
Score 2	0.0%
Score 3	20.0%
Score 4	0.0%

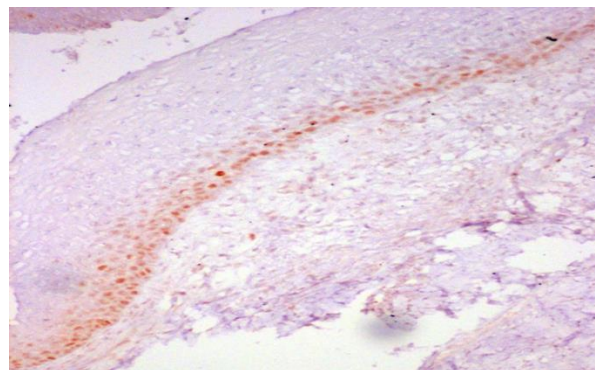


Fig. 2: Immunoreactivity for p53 protein showing mild nuclear staining(+1) in basal epithelial cell layer in CIN 1 (x100)

Discussion

In this study of 20 cases, the mean age of patients with premalignant lesions was 45.4 ± 10.6 . The peak incidence of premalignant lesions was seen in the 4th decade. The findings in the present study are similar to the study done by Rajaram S et al⁽⁵⁾ (52.1 ± 12.46 years), W. A Tjalma et al⁽⁶⁾ (52 years), V.M. Berlin Grace et al⁽⁴⁾ (44 years -CIN), Tan GC et al⁽⁷⁾ (50.3 years) and Astrid et al (45 years).⁽⁸⁾ In this study, pap smear with negative for malignancy showed p53 stain positivity in 40.9% of cases, LSIL -80% positivity and 90.9% was observed and p value of 0.000 (significant value). p53 positivity was higher in abnormal colposcopy and found to be statistical significant of p value - 0.003. Similar findings was observed in the study done by Goel Madhumati et al⁽³⁾ 2012 where p value was found to be < 0.25 .

In the study done by Shukla et al 2014,⁽⁹⁾ p53 immunoreactivity was found to be CIN1 22.2% with p value of 0.10. Another study by Krishnan Baskaran et al⁽¹⁰⁾ also showed that p53 expression is in CIN 1 was 35% and it had significant p value. In our study, in CIN 1 higher percentage of staining was observed in basal layer. Nuclear staining was majority noted in 26-50% staining. Similar finding noted in V.M. Berlin Grace et al⁽⁴⁾ study. In the study, Florina Vasilescu et al⁽¹¹⁾ observed that there was diffuse staining for cervical neoplasia and basal nuclei in the normal epithelium.

Contrary to this study, there were few studies which showed higher p53 positivity in CIN1 than CIN 2 and 3. Cheah PL et al 2002⁽¹²⁾ and Silvano Bosari et al⁽¹³⁾ 2005 showed 100% p53 positivity in CIN1 lesion when compared to high grade lesions of cervix. Studies

such as Sivano Bosari et al (2005)⁽²⁰⁾ and Cheah PL1 et al(2002)⁽¹²⁾ showed that there was 100% p53 positivity in low grade lesions of cervix. The p53 expression was found to be more in high grade lesions than mild dysplasia in studies such as Shukla et al in 2014,⁽⁹⁾ and Goel Madhumathi et al in 2012.⁽³⁾

Conclusion

In conclusion the expression of p53 was high in premalignant cervical lesion compared to nonspecific cervicitis due to high proliferative index and p53 marker can be used to differentiate these. In the present study, p53 expression was absent in inflammatory lesions and positivity was found in CIN1 lesions. This helps in identifying the subset of dysplastic lesions which need to be followed up more vigilantly to prevent their development into cancers. This could also be used as a backup for histopathology and also in cytology when there is ambiguity in knowing whether there is dysplasia or not.

References

1. Globocan 2012; 12 Dec 2013. www.globocon.iarc.fr(WHO international agency for research on cancer).
2. ICO information centre on HPV and cervical cancer (HPV information centre)2014www.who.int/hpvcntre.
3. Goel Madhumathi et al. Immunohistochemical expression of cell proliferating nuclear antigen (PCNA) and p53 protein in cervical cancer. Journal of obstetrics & gynaecology India Oct 2012;2(5):557-581.
4. V.M. Berlin Grace et al .Co-overexpression of p53 and bcl-2 proteins in HPV-inducedsquamous cell carcinoma of the uterine cervix. Gynecologic Oncology 91 (2003) 51-58.
5. Rajaram S et al. High-risk human papillomavirus, tumor suppressor protein p53 and mitomycin-C in invasive squamous cell carcinoma cervix. Indian Journal of Cancer, Vol. 43, No. 4, October-December, 2006, pp. 156-162.
6. Tjalma WA., Weyler JJ, Bogers JJ, Pollefliet C, Baay M, Goovaerts GC, Buytaert PM. The importance of biological factors (bcl-2, bax, p53, PCNA, MI, HPV and angiogenesis) in invasive cervical cancer. European Journal of Obstetrics & Gynecology and Reproductive Biology 2001;97(2):223-230.
7. Tan GC, Sharifah NA, Salwati S, Shiran MS, Hattaaz Ng HO. Immunohistochemical study of p53 expression in premalignant and malignant cervical neoplasms. Med & Health 2007;2(2):125-132.
8. Astrid Baalbergen et al. Prognosis of adenocarcinoma of the uterine cervix: p53 expression correlates with higher incidence of mortality. Int. J. Cancer: 121, 106-110 (2007).
9. Shukla S et al 2014.p53 and bcl2 expression in malignant & premalignant lesions of uterine cervix and their correlation with Human papilloma virus 16 & 18. South Asian Journal Cancer 2014 Jan-Mar;3(1):48-53.
10. Krishnan Baskaran, Santha Karunanithi, Inmozhi Sivakamasundari, Junior Sundresh N, Thamaraiselvi B, Swaruparani S. Overexpression of p53 and its role as early biomarker in carcinoma od uterine cervix. Int J Res Pharm Sci 2013;4(2):198-202.
11. Florina Vasilescu et al. P53, p63 and Ki-67 assessment in HPV-induced cervical neoplasia Romanian Journal of Morphology and Embryology 2009,50(3):357-361.
12. Cheah PL, Looi LM. p53 immunohistochemical expression: messages in cervical carcinogenesis. Pathology 2002;34(4):326-31.
13. Kalyani Raju, Shruthi Suresh Punnayanapalya, Narayanaswamy Mariyappa. Significance of p53, pRb and Ki-67 markers in Cervical intraepithelial lesion and Malignancy. Biomedical Research and Therapy2015,2(10):374-384.
14. Alessandra Eifler Guerra Goday et al. Expression analysis of p53, KI67 & bcl2 in premalignant lesions of cervix. Open journal of obstetrics & gynaecology vol 4 no:8 (2014)articleID:46740,8 pages.
15. Jingbo Wu et al. Detection and pathological value of papillomavirus DNA and p16INK4A and p53 protein expression in cervical intraepithelial neoplasia. Oncology Letters 7: 738-744, 2014.
16. Tosun G1, Sendag F, Zeybek B, CosanTerek M, Guven C, Zekiogly O, Bilgin O. Immunohistochemical expressions of p16 and p53 proteins in cervical intraepithelial neoplasia and in benign cervical tissue. Eur J Gynaecol Oncol. 2010;31(6):627-31.
17. Cher-Wei Liang, MDa, b, Ming-Chieh Lin, MDb, Chen-Hsiang Hsiao, MDb, Yi-Ting Lin, MSb, Kuan-Ting Kuo, MDb. Papillary squamous intraepithelial lesions of the uterine cervix: human papillomavirus-dependent changes in cell cycle expression and cytologic features. Human Pathology 2010;41:326-335.
18. Singh M et al. Co-expression of p53 and Bcl-2 proteins in human papillomavirus-induced premalignant lesions of the uterine cervix: correlation with progression to malignancy. Tumour Biol. 2009;30(5-6):276-85.
19. Abeer A. Bahnassy, Abdel Rahman N Zekri, Mahasaleh, Mohammad Lotayef, Manar Moneir, Osama Shawki. The possible role of cell cycle regulators in multistep process of HPV associated cervical carcinoma. BMC Clinical Pathology 2007;7:4.
20. Silvano Bosari MD et al p53 immunoreactivity in inflammatory & neoplastic diseases of uterine cervix. Journal of pathology: 2005 vol 169, issue 4,425-430.