

Rare case of Rupture Bicornuate Uterus

Mo Anish Hingora¹, Manish Pandya^{2*}

¹Resident, ²HDO, Dept. of Obstetrics & Gynecology, Scientific Research Institute, Surendranagar, Gujarat

***Corresponding Author:**

Email: drmanish.pandya@gmail.com

Abstract

Introduction: Uterine rupture in pregnancy is a rare and often complicate with a high incidence of fetal and maternal morbidity. Bicornuate uterus is a rare uterine anomaly result from incomplete fusion of the two Mullerian ducts during embryogenesis. Bicornuate uterus very rarely can lead to rupture of the uterus with high mortality and morbidity rates.

Keywords: Uterus, Pregnancy, Rupture Uterus, Bicornuate Uterus, Hystrectomy

Received:

Introduction

The female reproductive organs develop from the fusion of the bilateral paramesonephric (Mullerian) ducts at intra uterine 6-7 week to form the uterus, cervix, and upper one-thirds of the vagina. Bicornuate uterus is a rare uterine anomaly result from incomplete fusion of the two Mullerian ducts during embryogenesis. This leads to varying degrees of separation between two symmetrical uterine cavities ranging from partial separation to complete separation with no communication between the two cavities.^(1,2,12) Kidney and other urinary tract abnormalities are often associated with Mullerian ducts anomalies.⁽³⁾ Women with bicornuate uterus can have reasonable success – approximately 60% in delivering a living child.⁽⁴⁾ Rupture of the gravid uterus is a rare obstetric catastrophe with high mortality and morbidity. It is more common in multigravida or in scarred uterus and usually occurs at labor.⁽⁵⁾ Bicornuate uterus is associated with adverse reproductive outcomes and very rarely can lead to rupture uterus during the pregnancy.⁽⁵⁾ Herein, we reported a case of multigravida with second trimester rupture of bicornuate uterus.

Case Report

A 30 years un booked G₆P₅L₃A₁ (two FTND still birth because of severe PIH) at 20 weeks gestation with previous one caesarean section came to our hospital with complain of abdominal pain since 2 days with giddiness. On examination she was conscious, oriented, afebrile, dehydrated, severe pallor, PR-146/min, BP-86/58 mm of Hg, with 20 respiratory rate On abdominal examination there was generalized abdominal tenderness, loss of uterine contour, fetal parts felt superficially and absent fetal heart sounds. Suspecting uterine rupture confirmed with help of USG and urgent laparotomy under general anesthesia was planned with two unit of blood in hand. Abdomen opened by longitudinal incision. The intraperitoneal was full of blood and blood clots. A male dead fetus weighing 520gm delivered from right hepatic area. It was found that fetus was in abdominal cavity due to uterine rupture at right fundus of bicornuate uterus and placenta was adherent to uterine wall. As uterine repair was not

possible Obstetrics hysterectomy with bilateral Salphingo-Oophorectomy done by clamping, cutting and ligating the supports of uterus. Total 10 clamps were taken in trolley. Bladder was separated from one side of round ligament to another round ligament at uterovascular fold to lower border of cervix. Window was created at avascular area in broad ligament near infundibulum. First clamp at infundibulo-pelvic ligament then uterine artery clamped doubly at isthmus at 45 degree. Next clamp applied parallel to uterus in mackenrodt's ligament, Next clamp at level of utero-sacral ligament. Last clamp at the level of cervix and cut and clamp and uterus was taken out of abdominal cavity. All clamps applied bilateral and sutured by transfixation doubly one by one. She received one intra-operative and four post-operative blood transfusion. Injection calcium gluconate 10ml in 100ml of normal saline was given after 3rd blood transfusion. Except Hb - 4.9 gm %, rest routine blood and urine reports were within normal limits. Her post op period was uneventful.

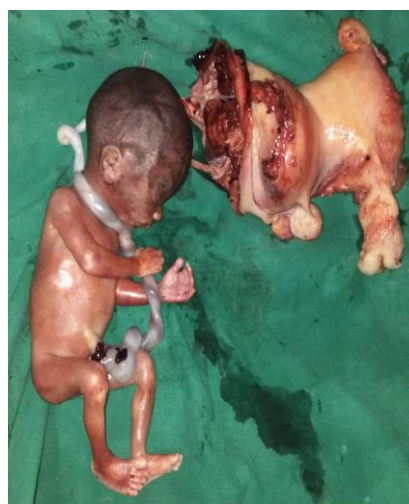

Fig. 1: Dead fetus with cord around neck with rupture uterus

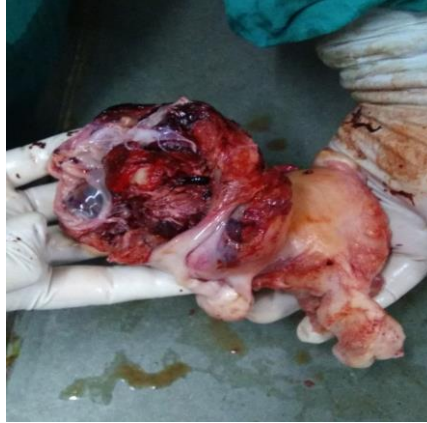

Fig. 2: Ruptured bicornuate uterus from right fundal area

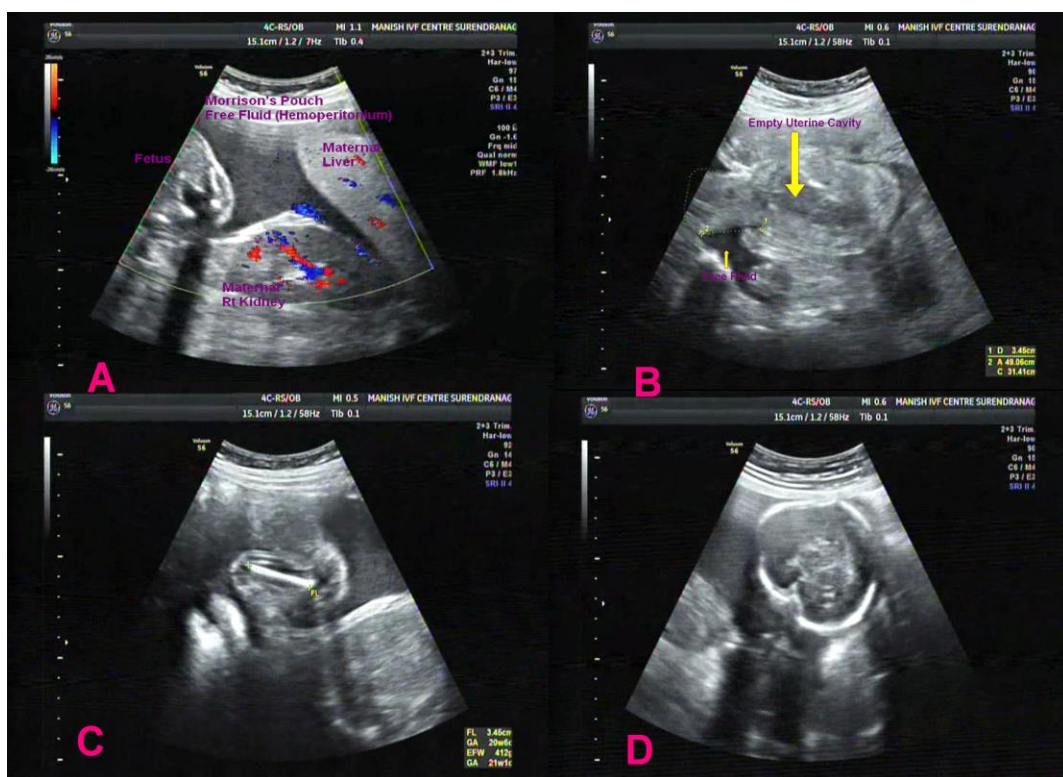


Fig. 3: USG findings of our case. (A) Fetus in Morrison's Pouch (B) Ruptured Uterus. (C) Femur length (D) Fetal head

Conclusion

This case highlights the fact that uterine rupture can occur when associated with uterine anomaly and previous LSCS. Early sonographic diagnosis has a major contribution in evaluation and management.

Discussion

Bicornuate uterus is composed of two "horns" separated by a septum. In humans, a bicornuate uterus is a type of uterine malformation. It is possible to diagnose a bicornuate uterus using USG specifically sonohysterography and MRI.⁽⁶⁾ However, as there is no indication to do such procedures on asymptomatic women. Pregnancy in a Bicornuate

uterus has a poor reproductive potential and requires close monitoring.⁽¹⁾ Woman with a complete bicornuate uterus has a 66% incidence of preterm delivery and a lower fetal survival rate.⁽¹²⁾ In asymptomatic women, the presence of bicornuate uterus may not be detected until during pregnancy or delivery.^(6,7) In our case patient presented with severe epigastric pain and abnormal uterine contour it was clear cut indication of uterine rupture initially. An urgent ultrasound examination had shown dead fetus in abdominal cavity rupture on fundal area of right cornu and free fluid intraperitoneally. Even after deterioration of the patients' condition, dropping of her hemoglobin, and USG finding of increased free fluid, the diagnosis was

clear. Immediate blood and fluid replacement therapy, and exploratory laparotomy were essential to save the patient's life.^(8,9) Obstetrical outcomes are generally reported to be better in cases of bicornuate uterus than in unicornuate uterus⁽²⁾ but in our case fetus was already dead.

The cornual pregnancy has been used in the literature to indicate pregnancy in a horn of an anomalous uterus⁽¹⁰⁾. However, the terms interstitial and cornual pregnancies, have been used interchangeably, cornual implantation describes those in the upper lateral uterine cavity, whereas, interstitial denotes those implanted within the proximal intramural portion of the tube.⁽¹⁰⁾ The thin muscular wall of the pregnant horn increases the risk of the horn ruptures.⁽¹¹⁾

Diagnosis of early first trimester prerupture is rare and remains challenging. Ultrasound in early pregnancy has a major role in the early diagnosis. MRI can be a useful noninvasive diagnostic tool.⁽¹¹⁾ Due to the scar following the uterine rupture, pregnancy is suggested to be avoided at least for one year.⁽⁵⁾ The subsequent pregnancy should be carefully monitored.⁽¹²⁾

Conclusion

This case highlights the fact that uterine rupture can occur in early pregnancy when associated with uterine anomaly. The clinician should be aware of this potentially life-threatening condition. Early sonographic diagnosis has a major contribution in evaluation and management.

References

1. Chan Y.Y., Jayaprakasan K., Tan A., Thornton J.G., Coomarasamy A., Raine-Fenning N.J. Reproductive outcomes in women with congenital uterine anomalies: a systematic review. *Ultrasound Obstet. Gynecol.* 2011;38:371–382.
2. Reichman D.E., Laufer M.R. Congenital uterine anomalies affecting reproduction. *Best Pract. Res. Clin. Obstet. Gynaecol.* 2010;24:193–208.
3. Elyan A., Saeed M. Mullerian duct anomalies: clinical concepts. *Ain Shams J. Obstet. Gynecol.* 2004;1:11–20.
4. Williams gynecology - third edition-2016, chapter 18, bicornuate uterus.
5. Singh N., Singh U., Verma M.L. Ruptured bicornuate uterus mimicking ectopic pregnancy: a case report. *J. Obstet. Gynaecol. Res.* 2013;39:364–366.
6. Nicolini U, Bellotti M, Bonazzi B, Zamberletti D, Candiani GB (Jan 1987). "Can ultrasound be used to screen uterine malformations?"
7. Jayaprakash S., Muralidhar L., Sampathkumar G., Sexsena R. Rupture of bicornuate uterus. *BMJ Case Rep.* 2011;28(October) pii:0820114633.
8. Hassan C.H., Karim A.K., Ismail N.A., Omar M.H. Case report of ruptured non-communicating right rudimentary horn pregnancy: an acute emergency. *Acta Medica (Hradec Kralove)* 2011;54:125–126.
9. Elsayegh A., Nwosu E.C. Rupture of pregnancy in the communicating rudimentary uterine horn at 34 weeks. *Hum. Reprod.* 1998;13:3566–3568.

10. Arleo E.K., DeFilippis E.M. Cornual, interstitial, and angular pregnancies: clarifying the terms and a review of the literature. *Clin. Imaging.* 2014;38:763–770.
11. Tsafirir A., Rojansky N., Sela H.Y., Gomori J.M., Nadjari M. Rudimentary horn pregnancy: first-trimester prerupturesonographic diagnosis and confirmation by magnetic resonance imaging. *J. Ultrasound Med.* 2005;24:219–223.
12. Kochar S., Prakash P. An unusual case of rupture of right horn of bicornuate uterus at eighteen weeks of gestation. *J. Obstet. Gynaecol. India.* 2012;62:694–695.
13. Williams Obstetrics 24th edition, chapter 31, Uterine Rupture.