

SURGICAL INTERVENTIONS FOR ECTOPIC PREGNANCY- A CLINICAL STUDY DONE IN A TERTIARY CARE CENTRE FOR THREE YEARS

Madhu L^{1,*}, Champa BV², Karthavya S L³

^{1,2}Assistant Professor, ³Intern, Department of Obstetrics and Gynaecology, Shimoga Institute of Medical Sciences, Shimoga, Karnataka, India

*Corresponding Author:

E-mail: drchampamadhu@gmail.com, karthavya92@gmail.com

ABSTRACT

Background and Objectives: Ectopic pregnancy (EP) is a rare but life threatening condition which accounts for major cause of death in first trimester. The medical management of EP is still controversial in advanced cases. This study throws light upon the management of EP surgically in both early and advanced cases. Surgical care proves definitive treatment and better outcome in advanced cases.

Methods: The study was conducted over a period of 3 years from January 2011 to December 2014 in a tertiary care centre. The cases diagnosed with EP were included in the study and appropriate surgical interventions were done. The observations obtained were analyzed with SPSS software.

Results: A total of 66 cases were evaluated in the study and tubal EP was more common in them (77%) and the mean age of mothers was 26.5 years. Rare extra tubal EP was also seen and specific management with excision of trophoblastic tissue was done but 60% of the tubal EP presented late and Salpingectomy was performed and the rest of 17% cases underwent Salpingostomy.

Conclusion: EP is potential life threatening condition which if treated early has good prognosis. Advanced cases have to be managed with open surgical methods than laparoscopic method rather than controversial medical management.

Keywords: Ectopic pregnancy, Salpingectomy

INTRODUCTION

Ectopic pregnancy (EP) is a potentially life-threatening condition which occurs in ~ 1% of pregnant women and still the major cause of maternal mortality in the first trimester of pregnancy. It accounts for approximately 10% of maternal deaths [1]. In most developed countries, the incidence of EP has increased considerably over the last 20 years and now accounts for 1-2% of all pregnancies [2-5].

Despite major advances, early diagnosis of EP is still a challenge for clinicians. [1, 6 and 7] In the past 20 years, the use of sensitive β hCG tests, high-resolution trans-vaginal ultrasound, and advances in laparoscopy (LS) have enabled the detection of EP without tubal rupture.

EP has a significant detrimental effect on future fertility and less than half of the women who experience EP will be able to conceive again [5]. Thus, preserving the fertility of women has been the main goal of treatment in EP for gynecologists and over the last five years systemic methotrexate (Mtx) has been used for conservative treatment [8, 9].

Timely diagnosis allows the clinician to consider the full range of treatment options. This is important since the focus of contemporary therapeutic management exceeds the narrow aim of immediate treatment success (i.e. elimination of the EP) and includes retaining optimal fertility for those women desiring future pregnancy.

Surgical interventions are still the mainstay in advanced cases and cases of ruptured EP. Salpingectomy is performed in ruptured EP and Salpingostomy is performed to preserve the fertility in future. Expectant management has the high risk of rupture of EP but medical advances with the therapy of Mtx have changed the view of treating EP. This study gives emphasis to the different surgical interventions followed for EP.

MATERIALS AND METHODS

The study was conducted over a period of 3 years from January 2011 to December 2014 in the Department of Obstetrics and Gynecology in a tertiary care centre. The cases diagnosed with EP clinically and radio-logically with the help of ultrasound were included in the study. Informed consent was obtained from each mother in an appropriate manner.

A total of 66 cases were included in the study and evaluated. Various surgical interventions like Salpingectomy, Salpingostomy and specific management like oophorectomy, fimbriaectomy and excision were performed. In advanced cases of ruptured EP, Salpingectomy was performed as an emergency procedure to save the life of mothers. This was a descriptive and longitudinal study which was performed over three years. The statistical data obtained thereby was analyzed using SPSS software and results were tabulated.

RESULTS

Over a period of three years, total of 66 cases were evaluated.

The demographic profile of these cases showed the mean age of 26.5years with 74% people originating from rural background. Majority of the mothers were illiterate and only 37% of the mothers had primary level education. In 66 cases, 20 cases (30%) were prim gravida and remaining 70% cases were multigravida. In 77% (51) of cases, tubes were the site of EP and 78% (40) of them presented with ruptured EP. The site of EP is represented in Table 1;

Table1: Site of EP

Site	Number of pregnancy(n=66)	Percentage
Tubal	51	77%
Extra tubal	15	23%

The description of extra tubal pregnancy is presented in Table 2;

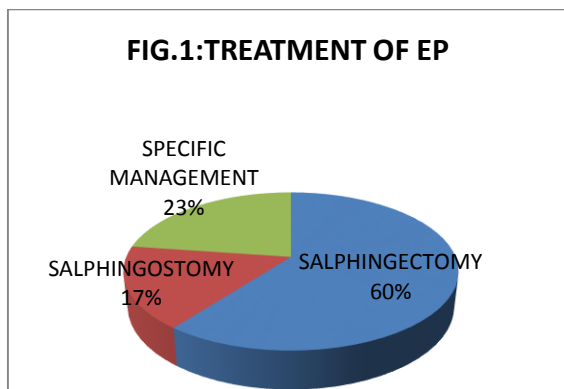
Table 2: Site of extra tubal pregnancies

Site	Number of pregnancy(n=15)	Percentage
Ovarian	3	20%
Cervical	1	7%
Interstitial	3	20%
True cornual	3	20%
Bicornuate	2	13%
CS* scar	1	7%
Tubectomy site	2	13%

*Caesarean scar

The surgical interventions opted for the cases were Salpingectomy in case of ruptured EP, Salpingostomy in cases which were diagnosed early with tubal EP and specific management by excision of the tissue in cases of extra tubal EP.

The surgical interventions are depicted as pie chart in Figure.1 which is as follows;



Clinical photographs of extra tubal EP (Figure 2):

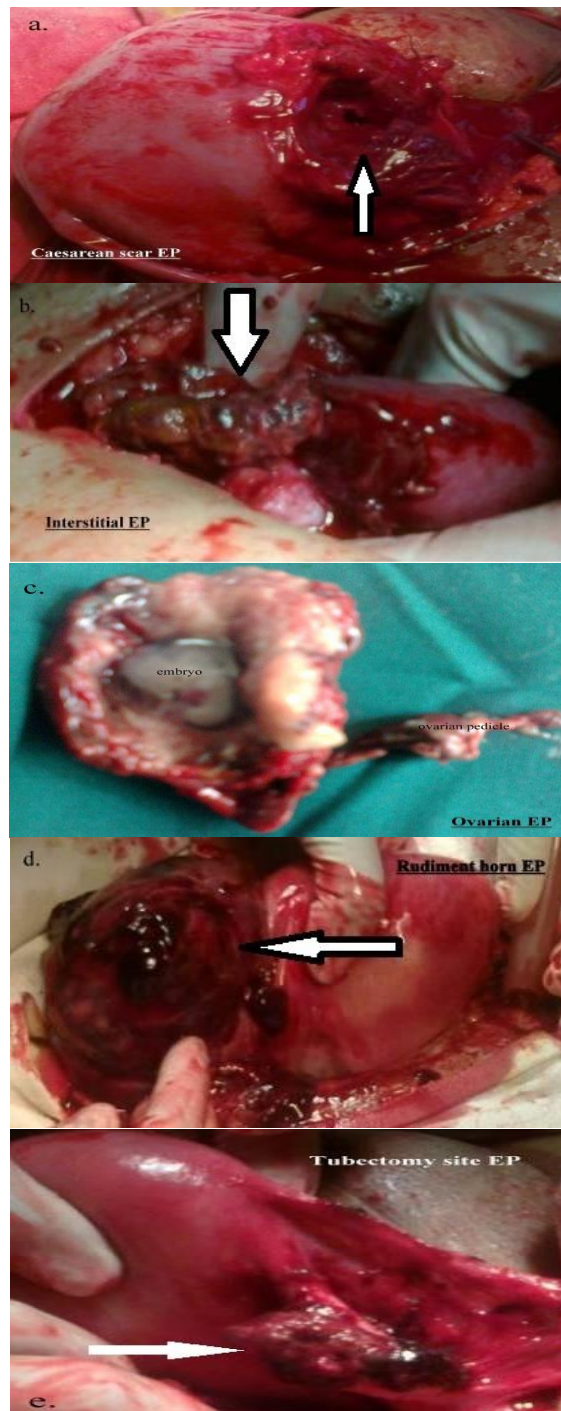


Figure 2: a-Caesarean scar EP; b-Interstitial EP; c-Ovarian EP; d-Rudimentary horn EP; E-Tubectomy site EP.

DISCUSSION

Ectopic pregnancy is still the potential life threatening condition if not treated properly. In this study we focus on surgical interventions mainly Salpingectomy and Salpingostomy for tubal EP

and specific excision of extra tubal EP. There are many studies suggesting the expectant management of EP and medical management of EP but in cases of advanced ectopic which have the potential of impending tube rupture it is dangerous to indulge in expectant management. Medical management with systemic Mtx has shown promising outcomes in cases which are diagnosed early but treating advanced cases of impending rupture with Mtx is still controversial as it poses a potential risk to the patient's life.

Surgical intervention by laparoscopic method is ideal for many of the cases but it poses risk when Salpingostomy is done as there is increased chance of persistence of trophoblastic tissue during the surgery. In this study all the cases were operated by open method i.e. laparotomy which nullifies the chance of persistence of trophoblastic tissue. From the analysis of surgical trials, it is clear that the number needed to harm with laparoscopic surgery for persistent trophoblast was 12, in other words when 12 women are treated by laparoscopy instead of laparotomy, there is one extra case of persistent trophoblast.

In this study 60% of patients underwent Salpingectomy as they presented late with tube rupture and rest of 11 cases out of 51 cases of tubal EP were managed by Salpingostomy. There are studies correlating treatment success in procedures of Salpingectomy and Salpingostomy and one of the review of cohort studies comparing fertility outcome after Salpingostomy and Salpingectomy for tubal EP showed no beneficial effect of conservative surgery on IUP rates, whereas the risk of repeat EPs was increased, although not significantly¹⁰.

In cases of extra tubal EP the open laparotomy method is beneficial because the site can be better visualized and complete removal of trophoblastic tissue is possible. The chance of retention of trophoblastic tissue is higher in laparoscopic method for these cases. So excision of the tissue and monitoring of serum β hCG has better prognosis in these cases.

There are previous studies which show surgery has better prognosis in advanced cases of EP. Medical management is only useful in early cases and specific management was done in our study for all EP cases and the results obtained in this study concur with old studies.

CONCLUSION

Ectopic pregnancy is a potential threat to life if not treated properly. Most of the cases of EP are tubal in origin and rare cases of extra tubal EP also can be seen. Surgical management is always best treatment in advanced cases and open method is better than laparoscopic method in ruptured and

advanced cases. Specific management must be done by surgical approaches rather than controversial medical therapy in high risk cases and extra tubal EP. There are very less studies conducted in fertility aspects after an EP and there is a need for further studies in that regard.

Compliance with Ethical Standards:

Conflict of Interest: All authors declare that they have no conflict of interest and there was no involvement of a pharmaceutical/other company.

Informed consent: Informed consent was obtained from all individual participants included in the study.

REFERENCES

1. T. Schmidt, D. T. Rein, D. Foth et al., "Prognostic value of repeated serum CA 125 measurements in first trimester pregnancy," *European Journal of Obstetrics & Gynecology and Reproductive Biology*; vol. 97, no. 2; p.168-173, 2001.
2. J. I.Makinen, "Ectopic pregnancy in Finland 1967-83: a massive increase," *British Medical Journal*; vol. 294, no. 6574; p.740-741, 1987.
3. J. Coste, N. Job-Spira, B. Aublet-Cuvelier et al., "Incidence of ectopic pregnancy. First results of a population-based register in France," *Human Reproduction*; vol. 9, no. 4; p.742-745, 1994.
4. Department of Health, *Report on Confidential Enquiries into Maternal Deaths in the United Kingdom 1994-1996*, HMSO, London, UK, 1998.
5. Centers for Disease Control, "Ectopic pregnancy in the United States 1990-1992," *Morbidity and Mortality Weekly Report*; vol. 44, no. 3; p.46-48, 1995.
6. M. Predanic, "Differentiating tubal abortion from viable ectopic pregnancy with serum CA 125 and β -human chorionic gonadotropin determinations," *Fertility and Sterility*; vol. 73, no. 3; p.522-525, 2000.
7. E. Kus, c, u, K. Vicdan, N. O. Turhan, S. O'guz, G. Zorlu, and O. G'okmen, "The hormonal profile in ectopic pregnancies," *Materia Medica Polona*; vol. 25, no. 3-4; p.149-152, 1993.
8. K. T. Barnhart, G. Gosman, R. Ashby, and M. Sammel, "The medical management of ectopic pregnancy: a meta-analysis comparing "single dose" and "multidose regimens," *Obstetrics & Gynecology*; vol. 101, no. 4; p. 778-784, 2003.
9. J. L. Glock, J.V. Johnson, and J. R. Brumsted, "Efficacy and safety of single-dose systemic methotrexate in the treatment of ectopic pregnancy," *Fertility and Sterility*; vol. 62, no. 4; p. 716-721, 1994.
10. Clausen I. Conservative versus radical surgery for tubal pregnancy. *Acta Obstet Gynecol Scand* 1996; 75:8-12.