

## MISSED INTRAUTERINE DEVICE WITH RECTAL PENETRATION: CASE REPORT

Prashant Joshi<sup>1,\*</sup>, Linthoi Rajakumari<sup>2</sup>

<sup>1</sup>Professor, <sup>2</sup>Postgraduate Resident, Department of Obstetrics & Gynaecology, Adichunchunagiri Institute of Medical Sciences, B G Nagara

**\*Corresponding Author:**

E-mail: joshpj@rediffmail.com; drjoshiobg@gmail.com

### ABSTRACT

*Intrauterine contraceptive device has been widely used and is commonly used as contraception in developing countries due to lower failure rate and the cheap cost with millions of women using it worldwide. The case report shows a missing Cu-T found in the abdominal cavity with its vertical stem penetrating into the rectum in a 20-year-old woman. Laparotomy with closure of rectal injury and uterine perforation with retrieval of the Cu-T was successfully done.*

**Keywords:** *Intrauterine device, Rectum, Uterine perforation*

### INTRODUCTION

Intrauterine contraceptive device (IUCD), is a widely accepted method of contraception. IUCD is a safe, effective and a low cost method when used as contraception and hence is widely used in developing countries.<sup>1,2, 3</sup> The provider must insert the IUCD correctly and follow up the users as one of the complications reported with IUCD is missing IUCD.<sup>4-6</sup> The prevalence rate of missing IUCDs in most studies varies between 0.5 to 2% of the IUCD users.<sup>5-9</sup>

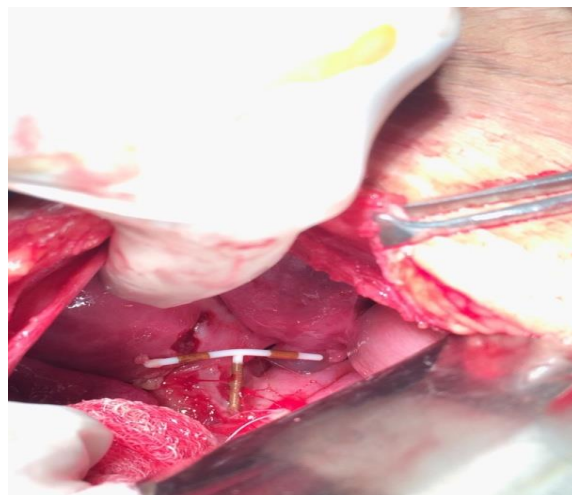
Sometimes IUCDs are placed by ancillary health care workers and follow up evaluations are not performed.<sup>10</sup> Some of the IUCDs can be missed where the threads of IUCD are not perceived by the patient or are not seen on speculum examination. One of the causes of a missed IUCD is uterine perforation<sup>11</sup> Regular self-examination for missing threads is useful for early detection of migrated IUCD.<sup>12</sup>

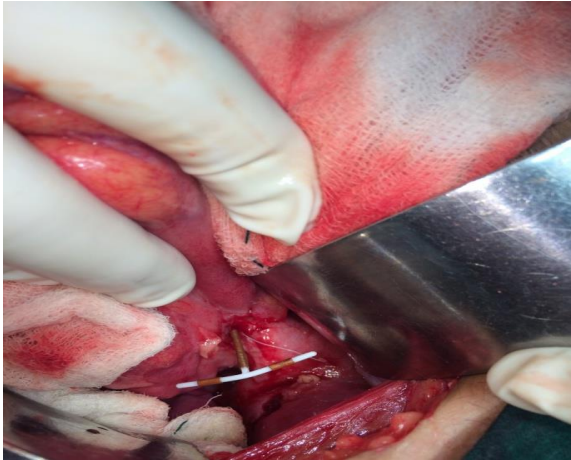
IUCD migration subsequent to uterine perforation is an uncommon but serious complication when inserted during postpartum period.<sup>13</sup>

### CASE REPORT

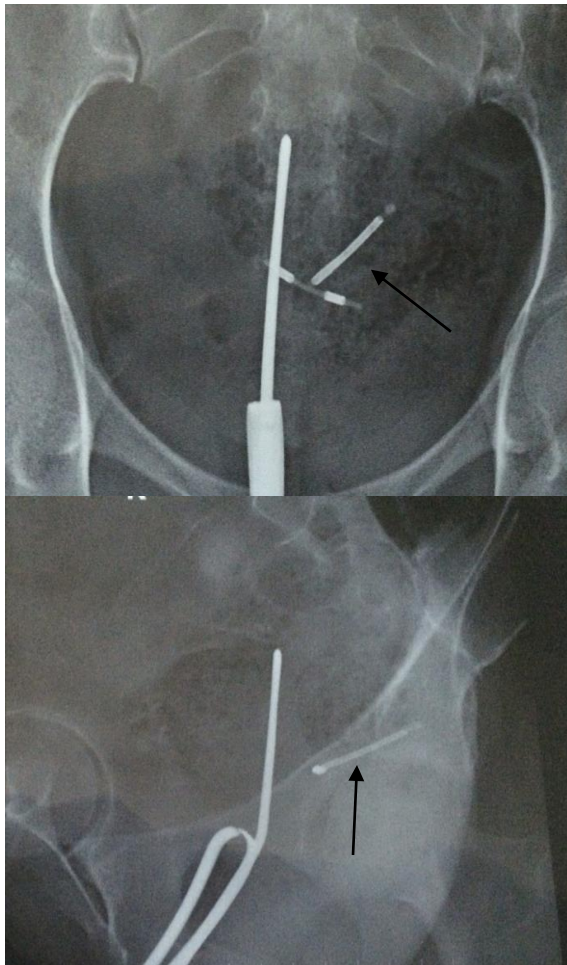
A 20-year-old lady (Para 1Living1) who had undergone previous normal vaginal delivery 6 months back was admitted to Adichunchunagiri Institute of Medical Sciences, B G Nagara after presenting with dull aching pain in the lower abdomen for 1 week. IUCD insertion was done a month earlier during the lactational period, i.e., 5 months after delivery in peripheral rural health care centre. On examination, her general condition was good. Abdomen was soft, minimal tenderness present in the supra pubic region. The IUCD strings were not seen on per speculum examination. Vaginal examination revealed cervical motion tenderness. Her abdominal radiograph (antero-posterior & lateral view fig 2) with uterine sound in the uterine cavity

revealed IUCD in the pelvis and trans-vaginal ultrasonography revealed an empty uterine cavity with features suggestive of IUCD in the pouch of Douglas. The patient was posted for emergency laparotomy. During surgery, omental adhesions were cleared from the uterus. After careful dissection, the vertical limb of the IUCD was seen below the serosa of the rectum. Uterine perforation over the posterior wall of uterus of about 1 X 1 cm noted. The IUCD was removed and the serosal tear at the rectosigmoid junction repaired. Uterine perforation was closed and an abdominal drain was kept before closing the abdomen. Patient was kept nil by oral for 24 hours. Post-operative recoveries were uneventful.





**Fig 1: Arrow showing intrauterine contraceptive device tip embedded in rectal wall.**



**Fig. 2: Abdominal radiograph of the missing IUCD AP (right) and lateral view (left)**

## DISCUSSION

IUCD is a safe, effective and reversible mode of long-term contraception but may be associated with certain morbid complications like uterine perforation. Uterine perforation by an IUCD

is reported as a complication in 0.87 per 1000 cases, varying from 0.05 to 13 per 1000 insertions<sup>14</sup> Uterine perforation during Cu-T insertion is one of the rarest complications and 30% of which are asymptomatic and can be presented with serious complications if not diagnosed early.<sup>15</sup> The IUCD can get embedded in the uterine wall and later forced through the uterine wall by uterine contractions into the abdomen and internal viscera<sup>16</sup> The perforation is thought to occur during insertion or due to chronic inflammatory reaction to copper containing foreign object leading to gradual erosion through uterine wall. Perforation of the rectum or sigmoid colon by an IUCD can lead to complications like peritonitis and stricture... A misplaced IUCD may be diagnosed by noninvasive methods, such as X-ray and ultrasound of the abdomen and pelvis. Invasive diagnostic methods are uterine sounding and hysteroscopy. A computed tomography scan is recommended if bowel perforation is suspected.<sup>17</sup> There are only a few reports of IUCDs dislocating into the rectum.<sup>18</sup> Now a days laparoscopic removal of the IUCDs and intra corporeal suturing of the rectal perforation can be easily done but it depends on the surgeon's skills and availability of resources.<sup>19</sup>

## CONCLUSION

It is recommended that IUCDs should be inserted after proper case selection by trained medical professionals and the patient should be educated and counseled about feeling for the IUCD thread after every menstrual cycle and that a proper follow up is needed when the woman is not able to feel the thread.

## REFERENCES

1. S.K. Chaudhuri. Intrauterine Devices (IUDs). Practice of Fertility Control: 7th edition;111.
2. Barsual M, Sharma N, Sangwan K. Three hundred and twenty four cases of misplaced IUCD – a five years study. Trop Doct.2003; 33: 11-12.
3. Zafar M, Murtaza N and Saeed S. Two displaced intrauterine contraceptive devices (Copper-T). JCPSP 2004; 14: 427-29.
4. Centre for disease control. Intrauterine contraceptive devices in family planning methods and practices in Africa. 3rd edition. C.D.C Atlanta, Georgia. 1983.
5. Sekadde- Kigandu C, Mwathe E G, Ruminjo J K et al. Acceptability and discontinuation of Depoprovera, IUCD and combined pill in Kenya. East Afr Med J 1996; 73 (12):786-94.
6. Farr G, Amalya R, Acosta M, Ekvempu C, Kisninci H. Clinical performance of Tcu-380A and loop IUDs in three developing countries. Contraception 1995; 52 (1): 17-22.
7. Fakeye O. IUDs: Its Effectiveness and Acceptability at Ilorin. Nig Med Practitioner 1986; 12 (1, 2): 38-43.
8. Lawal S O, Giwa- Osagie O F, Ogedengbe O K, Usifoh C. A review of IUCD related problems in Lagos University Teaching Hospital (LUTH). West Afr J of Med 1993; 12(3):144-7.
9. Mongaza N. Misplaced intrauterine device: A Case report. Int J Gynaecol Obstet 1984; 22: 421-4.

10. Noura Y, Rakrouki S, Gargouri M, Fitouri Z, Horchani A. Intravesical migration of intrauterine contraceptive device complicated by bladder stones. A report of six cases. *Int Urogynaecol J* 2007; 18: 575-8.
11. Rani SS, Krishna S. Multiple intrauterine devices in a pregnant uterus. *J Obstet Gynecol India* 2005; 53: 551-2.
12. Chang HM, Chen TW, Hsieh CW, Chen CJ, Yu JC, Liu YC et al. Appendicitis: A Case Report. *World J Gastroenterol* 2005; 11: 5414-5.
13. Cumming GP, Bramwell SP, Lees DA. An unusual case of cystolithiasis: A urological lesson for gynecologists. *Br J Obstet Gynaecol.* 1997;104: 117–120. Grimaldi L, de Giorgio F, Andreotta P, D'Alessio MC, Piscicelli C, Pascali VL. Medicolegal aspects of an unusual uterine perforation with multiloop-Cu 375R. *Am J Forensic Med Pathol.* 2005;26:365–366.
14. Phupong V, Sueblinvong T, Pruksanaonda K, Taneapanichskul S, Triratanachat S. Uterine perforation with Lippes loop intrauterine device associated actinomycosis: A case report and review of the literature. *Contraception.* 2000;61:347–350.
15. Carson SA, Gatlin A, Mazur M. Appendiceal perforation by Copper-7 intrauterine contraceptive device. *Am J Obstet Gynecol.* 1981;141:586–587.
16. Istanbuluoglu MO, Ozcimen EE, Ozturk B, Uckuyu A, Cicek T, Gonen M. Bladder perforation related to intrauterine device. *J Chin Med Assoc.* 2008;71:207–209.
17. Sepulveda WH. Perforation of the rectum by a Copper-T intra-uterine contraceptive device; a case report. *Eur J Obstet Gynecol Reprod Biol.* 1990;35:275–278.
18. Bitterman A, Lefel O, Segev Y, Lavie O. Laparoscopic Removal of an Intrauterine Device Following Colon Perforation. *JSLs: Journal of the Society of Laparoendoscopic Surgeons.* 2010;14(3):456-458. doi:10.4293/108680810X12924466006963.