

Cervical Ectopic Pregnancy – Diagnosed or Misdiagnosed

Joylene D'Almeida^{1,*}, Prashanth Hegde², Sujaya V Rao³

¹Assistant Professor, ^{2,3}Professor, Father Muller Medical College and Hospital

***Corresponding Author:**

E-mail: Joylene16@yahoo.com

ABSTRACT

Cervical ectopic pregnancy is defined as the implantation of an ectopic pregnancy in the cervix. The actual incidence is < 1%. Though rare, it requires a strong degree of clinical suspicion combined with ultrasound evidence to arrive at the diagnosis. The management of a cervical ectopic includes medical and surgical options. Medical options include using drugs like methotrexate and etoposide. Surgical options primarily include curettage and tamponade. Hemorrhage is a dreaded complication of a cervical ectopic and a torrential haemorrhage warrants an emergency hysterectomy.

Keywords: cervical ectopic, haemorrhage.

INTRODUCTION

Cervical ectopic is defined as the implantation of a pregnancy in the endocervical canal and is a rare entity. The diagnosis and management of a cervical ectopic can be a challenging obstetrical entity. There has been a dramatic change in the outlook of the management of a cervical ectopic. There was a time when the impending danger of uncontrolled hemorrhage in a cervical ectopic, warranted an emergency hysterectomy. But presently, fertility sparing treatment options are the ray of hope.

The following are two interesting and unusual presentations of cervical ectopic pregnancies

CASE ONE

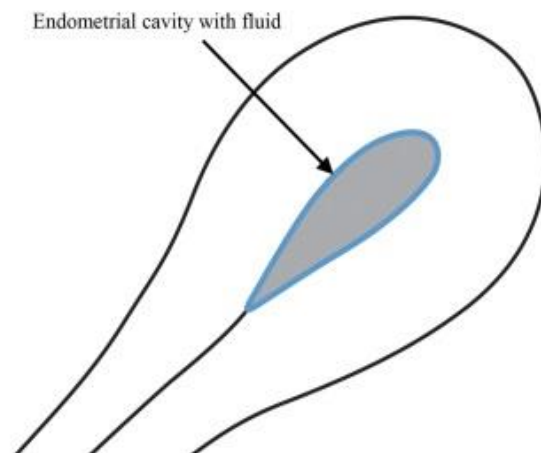
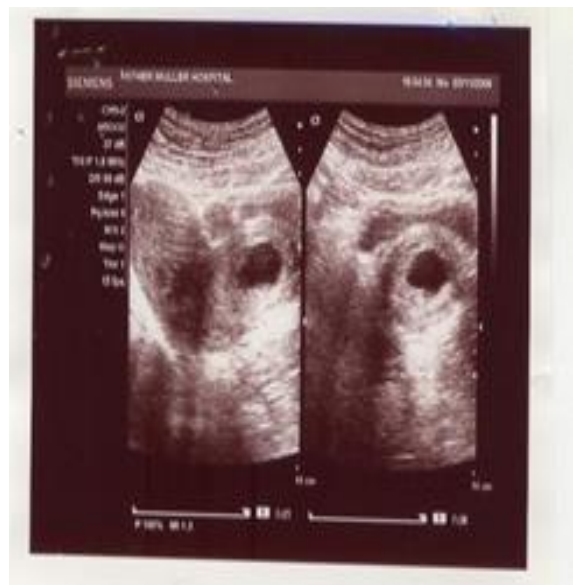A 24 year old nulliparous lady who had been married for 2 ½ months, presented to the emergency with lower abdominal cramping, burning micturition, bleeding per vagina and vomiting since two days. She had her last menstrual period 6 weeks prior to the incident.

On examination she was hemodynamically stable. On per speculum examination bloody mucoid discharge from cervix was seen and cervix enlarged and had a “Drumstick like appearance”. There was ballooning of the cervix seen. Pelvic examination revealed an 8 weeks pregnancy with enlarged cervix and unremarkable adnexa. Her systemic examination was within normal limits.

Her investigations revealed that she had a positive urine pregnancy test and also had 10 to 15 pus cells on her urine microscopy (urinary tract infection).

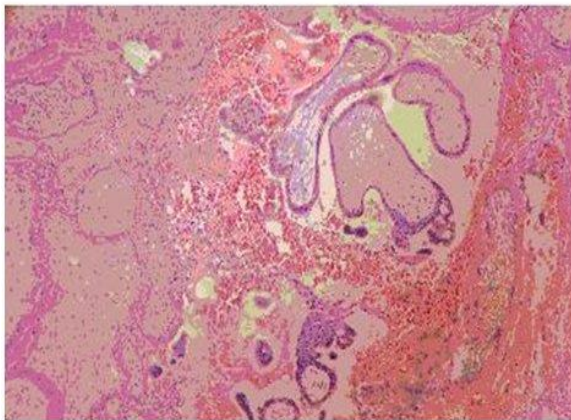
When a ultrasonography of the pelvis was done it was found that the uterus was enlarged and endometrial cavity was empty. The cervix was also enlarged. Within the cervix, a sac like structure (3 x 2 cm) was seen with a well-defined trophoblastic rim in the endocervix. There was no evidence of embryo within. The final impression was of retained products

of conception in the cervical canal and a possibility of cervical ectopic was suggested.



Therapeutic options were discussed with the patient and she was posted for a examination under anaesthesia followed by surgical evacuation. Preoperative preparations were done with adequate compatible blood reserved for transfusion.

Intra-operatively was the ovum forceps was negotiated gently through a partially opened external os A *gush of watery fluid* 8 to 10 cc was noted. As evacuation was carried out, moderate amount of bleeding was noted and gentle endocervical curettage was done. Hegars dilator was passed to ensure that the internal os was closed. An endometrial sampling was done and products of conception and endometrial samples were sent for histopathology.



A 30 ml foleys catheter bulb was inserted into the endocervical canal and the foley s bulb distended with normal saline to have a tamponade effect. The foleys catheter was removed the next day and the patient was symptomatically better. She was discharged on antibiotics. The histopathology report of the endocervical tissue revealed products of conception. The endometrial tissue showed the classical "arias Stella reaction". The repeat urine pregnancy test was negative which ensured complete evacuation.

CASE TWO

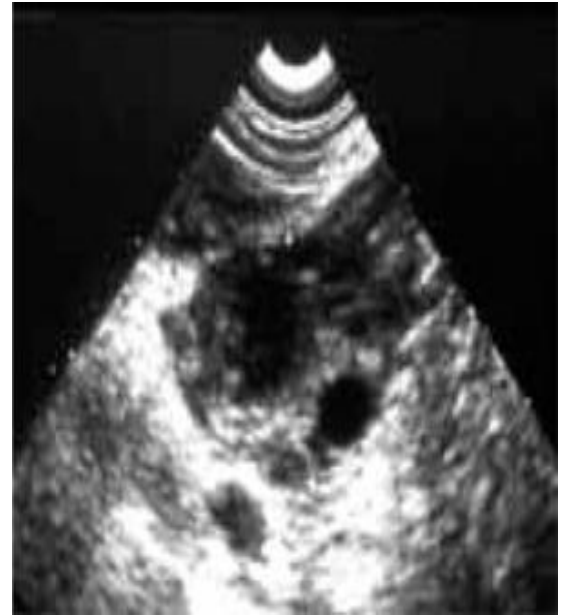A 30 year old multiparous lady, para 2 living 2 with a history one previous caesarean section. She was married for 12 Year. She presented to the emergency with complaints of bleeding per vagina, post coitally. The bleeding was painless, profuse and associated with clots. Her last menstrual period was 10 days back. Her menstrual cycles were once in 25 days.

The patient was hemodynamically stable and on **per speculum** examination there was bloody mucoid discharge from cervix and cervix was enlarged and vagina filled with clots. On pelvic examination was uterus bulky and there were no

vaginal tears. Systemic examination was within normal limits.

The urine pregnancy test was found to be weakly **positive** and haemoglobin was 11.5 g/dl. All other investigations were within normal limits.

An ultrasound revealed that the uterus was enlarged and endometrial cavity was empty. There was a left ovarian cyst with debris and no gestational sac seen. There was hyperechoic mass with free fluid in left adnexa. A final impression of a Left ovarian hemorrhagic cyst /ectopic pregnancy was made.



Our suspicions were strengthened when the patient had a fresh profuse bout of bleeding after every transvaginal ultrasound.

The patient was admitted with the suspicion of a ruptured hemorrhagic cyst .She was treated with antibiotics and a constant hemodynamic monitoring was done. A serial monitoring of serum b HCG and hemoglobin estimation was done.

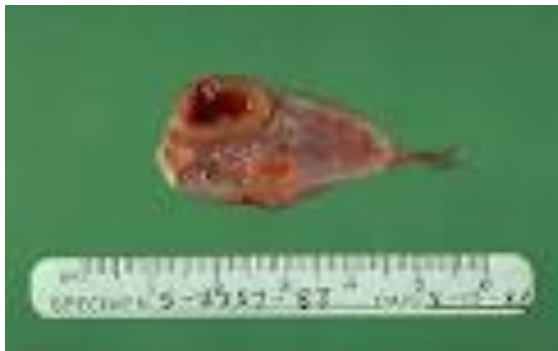Date	B HCG levels MIU/ ml	Hemoglobin. G / DL
DAY ONE	1408.00	10.9
DAY TWO	6715	9.7
DAY THREE	15408	9.8
DAY FOUR	1840	8.6

Seven days after admission, patient had a profuse bout of bleeding and due to the dropping trend of haemoglobin a decision for an examination under anesthesia and exploratory laparotomy was

made. Preoperative preparations were made, with adequate compatible blood reserved for transfusion.

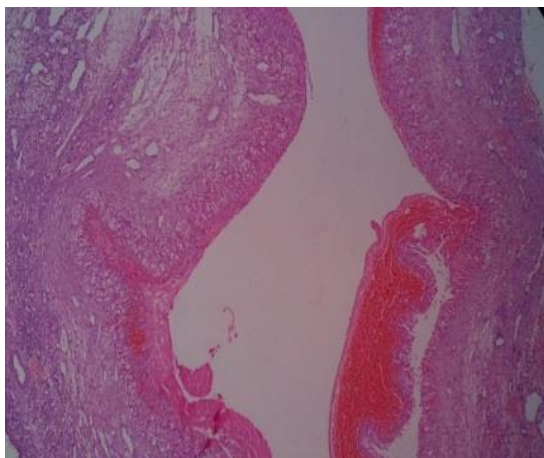
Intra-operatively: Ovum forceps was negotiated gently through a partially opened external os and as evacuation was carried out, greyish white tissue from the cervical canal was obtained. A gentle endocervical curettage done. Hegar's dilator was passed to ensure the internal os was closed.

A **30 ml foleys catheter bulb** was inserted into the endocervical canal, bulb distended with normal saline to have a tamponade effect. Intraabdominally, a left ovarian cyst 4 x 5 cm and minimal hemorrhagic ascites was present. Ovarian cystectomy with evacuation of clots was done.

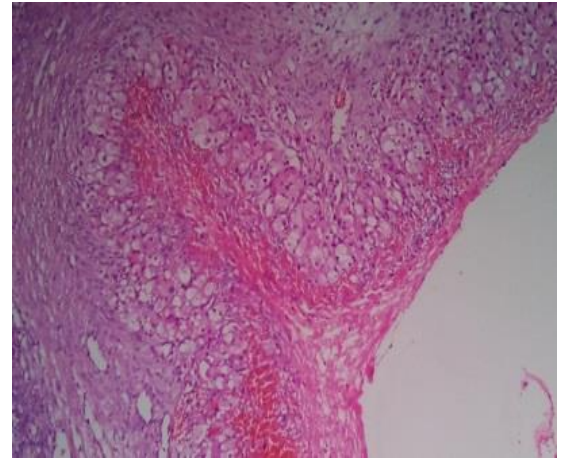


On follow up a repeat Urine pregnancy test showed a gradual decline in positivity and was negative eventually. Patient had her next menstrual cycle one and a half months after the evacuation procedure.

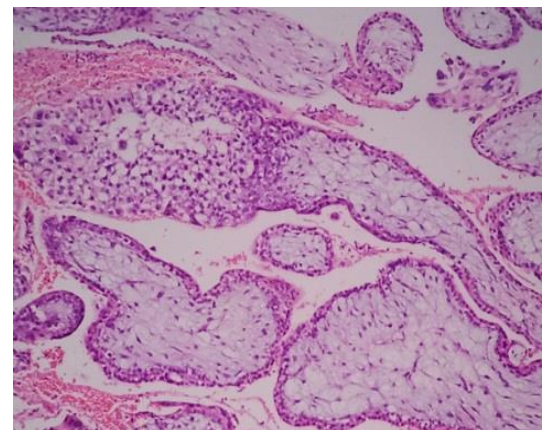
Histopathology revealed that the ovarian tissue had luteinised cells. The endocervix was lined by trophoblasts and chorionic villi. Hence this confirmed the diagnosis of a cervical ectopic pregnancy.



Fragments of ovarian tissue with areas of hemorrhage



Luteinised granulosa cells.



Endocervix, Chorionic villi, lined by trophoblasts, myxoid stroma.

DISCUSSION

Cervical ectopic pregnancy is an entity was first described in 1871.¹ The Incidence of cervical ectopic is < 1 % and 1 : 18000 live births.² The diagnostic dilemma faced by gynaecologists is to distinguish it from incomplete abortions, as in our second case. An empty uterine cavity with clots in the cervix, in both cases usually leads to confusion.

Prior to two decades, clinical diagnosis of cervical pregnancy was made when curettage for presumed incomplete spontaneous abortion resulted **in uncontrollable bleeding warranting emergency hysterectomy**. Hence it was a retrospective presumptive diagnosis. The mortality in cases of cervical ectopic was high, around 21 %. Though the exact aetiology remains unknown, the following theories have been postulated:

- ▶ It could be due to an accelerated **migration** of fertilized ovum through uterus
- ▶ Change in the ability of the **endometrial lining** to accept implantation

- ▶ Damage to endocervical canal could predispose to an ectopic in the cervix. Eg: damage due to prior cervical curettage

The actual diagnosis of a cervical ectopic pregnancy requires a high index of clinical suspicion. The most common symptom is first trimester bleeding per vagina. Abdominal cramping is also seen in 1/4 of cases. In most cases on examination a **bulky distended bluish** cervix is seen on per speculum.

The clinical course of a cervical ectopic is such that higher the trophoblastic implantation in the cervical canal, the longer the duration of cervical ectopic and greater its capacity to grow and cause haemorrhage.

The following are the radiological signs or evidence of a cervical ectopic:

- ▶ **RUBINS CRITERIA**³: Here there is a closed attachment of gestational sac and placenta to cervix, **cervical glands are seen opposite to site of implantation** and the placental location is below uterine vessels.
- ▶ **RASKIN CRITERIA**⁴: There is an enlargement of cervix with uterine enlargement, **absence of an intrauterine gestational sac** and diffuse amorphous intrauterine echoes on ultrasound.
- ▶ **SLIDING SIGN** : During TVS , when the sonographer applies gentle pressure on the cervix with probe the gestational sac of **an abortus slides against the endocervical canal**.¹
- ▶ Colour Doppler would reveal **Peri trophoblastic blood flow** from an active vascular supply to the conceptus. MRI is the investigation of choice, used to confirm the diagnosis.

However as in the above cases, during curettage, when the cervical contents are manipulated if it results in rupture of gestational sac as evident by a leaking **of liquor** and this is confirmatory of a cervical ectopic. Ultimately, an endometrial sampling sent for histopathological analysis showed **ARIAS STELLA reaction** that strengthened the diagnosis.

The treatment of a cervical ectopic includes medical and surgical modalities. Medical management includes the following:

- **Chemotherapy**: using drugs like Methotrexate and Etoposide. 80 % success with Methotrexate has been noted.⁵
- **Feticide**: Intra amniotic instillation of 3 – 5 ml of 2 meq of potassium chloride or methotrexate (1 – 1.5 mg/ kg) under U S G guidance.
- **Methods That Help by Reduction in Blood Supply**: Angiographic embolisation and also Laparoscopic assisted uterine artery ligation to help prevent torrential haemorrhage.

Surgical methods of management include **Curettage with tamponade** and a last resort peripartum Hysterectomy in cases with intractable haemorrhage, in cases of cervical pregnancy with advanced gestation and in parous woman not desiring fertility.

The risk of recurrence showed s 5 % risk of a future tubal ectopic pregnancy and 3 % repeat cervical pregnancy.⁶ Among the numerous studies, one at St George's Hospital, London, UK⁷ revealed that all women with CEP can and should be managed conservatively. Hirakawa et al⁸ showed that uterine artery embolisation along with the administration of methotrexate is effective in treating cervical ectopic pregnancy with vaginal bleeding while allowing the preservation of fertility.

CONCLUSION

Though cases of cervical ectopic pregnancy are rarely reported, the current rising trend in ART procedures and repeated curettage in the cervical region done for incomplete abortions could be predisposing. The diagnosis requires a sharp degree of clinical suspicion aided with high resolution TVS. Medical and minimal invasive surgical modalities have shown promising results. **Fertility sparing treatments** should be the ray of hope for nulliparous women.

The management has to be prompt and vigilance is required as torrential hemorrhage as a complication can be life threatening.

REFERENCES

1. Lawrence M. Leeman, MD, MPH; Claire L. Wendland, MD. Cervical Ectopic Pregnancy-Diagnosis With Endovaginal Ultrasound Examination and Successful Treatment With Methotrexate Arch Fam Med. 2000;9:72-77.
2. Bouyer J, Coste J, Fernances H, Pouly JL, Job Spira N. Sites of ectopic pregnancy: a 10 year population based study of 1800 cases. Hum Reprod 2002; 17: 3224-30.
3. Rubin IC. Cervical pregnancy. Surg Gynaecol Obstet 1911; 13:625-633.
4. Raskin MM. Diagnosis of cervical pregnancy. Acta Obstet Gynaecol Scand.1994; 73:734-736.
5. Jurkovic D, Hacket E, Campbell S. Diagnosis and treatment of early cervical pregnancy. Ultrasound Obstet Gynaecol.1996; 8:373-380.
6. Marcovici I, Rosenzweig BA, Brill AI, Khan M, Scommegna A. Cervical pregnancy. Obstet Gynaecol Surv 1994; 49; 49-55.
7. E. Kirk, G. Condous, A. Khalid, Z. Haider, T. Bourne. Abstract from posters. P04.13 Conservative management of cervical ectopic pregnancy .31 August–4 September 2004, Stockholm, Sweden.
8. Masakazu Hirakawa, Tsuyoshi Tajima, Kengo Yoshimitsu, Hiroyuki Irie. Uterine Artery Embolization Along With the Administration of Methotrexate for Cervical Ectopic Pregnancy: Technical and Clinical Outcomes AJR 2009; 192:1601–1607.