

A rare case of procidentia with rectal prolapse: A revolutionary change needed in the delivery practices in rural India

Dhwani Mehta^{1*}, Charmi Pawani², Nimish Pandya³

^{1,2}Post Graduate Student, ³Professor and HOD, Dept. of Obstetrics and Gynecology, Gujarat Adani Institute of Medical Science, Bhuj, Kutch, Gujarat, India

***Corresponding Author: Dhwani Mehta**

Email: researchguide86@gmail.com

Received: 1st September, 2018

Accepted: 22nd October, 2018

Abstract

Witnessing Multigravida, Grand Multigravida and Great Grand multigravida pregnancy is very usual and common in the Kachch district of Gujarat, India. Kachch happens to be the largest District of India with majority of population living in the rural area who are illiterate and believe in the norm of "Home delivery: Safe delivery". In the era of 20th century where a majority of us are happy with normal labour conducted by a skilful obstetrician at the hospital with the simultaneous assessment by the paediatrician there occurs a significant population nesting in rural corners who still abide by the traditional birth practices with "The Normal Dia Labour" unaware of its aftermath. A 59 year old, Widow, Female Patient P5L2D3 with all full term normal vaginal delivery conducted at Home presented to G.K. General Hospital (the only tertiary referral centre in the entire district) with inability to pass urine and with something coming out per vaginam. On examination it was a case of long standing procidentia with decubitus ulcer with purulent exudation and simultaneous contamination of it with pus and faecal matter from the surrounding rectal prolapse. Surgical correction by vaginal hysterectomy and repair of rectal prolapse was done with building up of perineum - a surgery which was a difficult nut to crack for the Gynaecologists and Surgeons. With increased parity and poor interval spacing with improper perineal support during the labour, the perineum becomes lax and the ligament and supports of the uterus become asthenic, flaccid. This shall present with pelvic organ prolapse in the peri-menopausal age, menopausal and post-menopausal age group. The ladies in the rural Indian setting believe it to be a social stigma and thus rarely these cases reach the hospital for intervention.

Keywords: Multigravida, Procidentia, Rectal prolapse, Decubitus ulcer, Cystocoele, Vaginal hysterectomy, Perineum.

Introduction

Pelvic Organ prolapse is defined as downward displacement of pelvic organs, resulting in herniation of those organs into or through the vagina.¹ It's a Latin word derived from Pro - 'Forward', labi- 'to slide'. Prolapse is a 'HERNIA' and the hernial portal is 'Levator Hiatus'.¹ It occurs in women of all ages, especially in those who have delivered large babies or those who have had exceedingly long pushing phases.² Other risk factors being smoking, obesity, connective tissue disorders, and obesity. Nevertheless, vaginal child birth probably plays a major role. There are distinctive fascial defects caused by vaginal childbirth and impairment of levator ani through pudendal nerve trauma. Levator Hiatus is the most critical soft tissue impediment to vaginal childbirth.³ The pelvic floor muscle that makes its opening has to undergo a degree of distension that would rupture any other skeletal muscle: with major trauma occurring in the normal vaginal deliveries in the primipara or be it an operative one. It is most commonly seen in multigravida patients and especially those patients who have deliveries conducted by Dia or traditional birth attendants.⁴⁻⁶

Case

A 59 year old female patient, P5L2D3, presented to the emergency department with history of trauma three days back with inability to pass urine since two days with abdominal pain with something coming out per vaginam since last 12 months she had attained menopause at an age

of 49 years and no other systemic illness. In her obstetric history, she had Five normal vaginal delivery conducted by Dia at her village out of which only two survived.

Upon Examination

Per abdomen was soft and non-tender with lower abdominal fullness with bladder full. Local examination revealed a uterovaginal prolapse of third degree with Rectal prolapse.

Per speculum examination revealed third degree uterovaginal prolapse, with third degree cystocoele with rectocoele.

Per vaginam examination revealed complete procidentia, Uterus was post-menopausal sized, Atrophic, bilateral fornices were non tender and clear, a skin tag was present between urethral opening and anterior vaginal wall. The whole of it was contaminated with purulent exudation and faecal mass with decubitus ulcer. The utero cervical length was approximately of 6-7 cm.

Per Rectal examination rectal mucosal prolapsed present of approximately 7*7 cm.

Immediately culture and sensitivity swabs were collected from purulent exudation which revealed ESBL (Escherichia Coli species) and Acinetobacter species.

Bladder was immediately catheterized and urine samples were sent for culture and sensitivity which reported no Significant Bacteriuria. Patient was no able to pass urine voluntarily therefore was kept catheterized and antibiotics were started for purulent exudation and daily dressing with

glycerine and magnesium sulphate crystals was done twice to decrease the edema.

USG: urinary bladder over distended with a two 6 mm calculus with foley's bulb in situ, uterus normal sized with no mass, with minimal free fluid in the pelvis with third degree UV prolapsed as uterus no seen per abdomen. All laboratory investigations were within normal limits including kidney function tests. Chest X ray, 2 D echocardiography and ECG were within normal limits. Patient was the posted for surgery after seeking surgical opinion and pre anaesthetic consent.

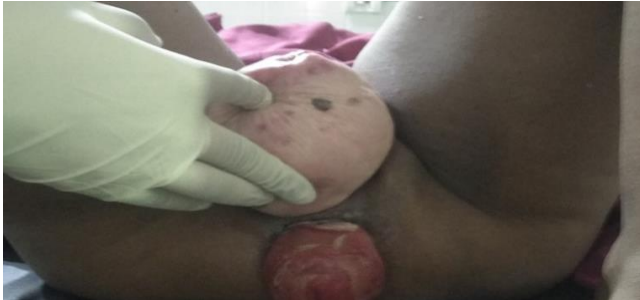

Fig. 1: Pre-operative

Operative Note

The patient was taken for surgery where vaginal hysterectomy was planned with repair of rectal mucosal prolapse. Epidural Anaesthesia was administered and patient was given lithotomy position. Sterile painting and draping was done with betadiene solution. There was a huge coconut sized prolapse – Procidentia with huge cystocoele and rectocoele. Rectum was four fingers below perineal skin and anal canal. There was a small skin tag between posterior vaginal wall and anterior wall of rectum with no perineum intervening and it was a complete perineal tear. The Uterocervical length was 8 cm and upon sounding the bladder, the cystocoele extended until external os of cervix. Catheter was passed and urine drained. 200 ml of Normal Saline with Adrenaline Infiltrated around the cervix – in the anterior, lateral and posterior wall of cervix. A circular Curvilinear Incision was made one finger above the external os transversely taking care of urinary bladder. Incision was extended laterally. Posterior incision was extended in a 'V' shaped manner four finger above the external os. Vaginal wall was separated with help of sharp dissection, lower flap dissected downwards and upper flap dissected upwards. Curved fine dissecting scissors was introduced between anterior vaginal wall and urinary bladder. It was cut until Transverse vaginal Sulcus until the urethra at vesico uterine junction. With the help of blunt dissection urinary bladder fascia was dissected on right and left side until the pubic rami achieving hemostasis simultaneously. Posteriorly, in between the two uterosacral ligaments, pouch of doughlas and peritoneum was identified which was thickened, pouch of doughlas was opened and held with scissors. Fundus of the uterus was pushed forwards anteriorly. Bladder held by assistant surgeon so that the vesico cervical ligament becomes prominent and was cut with sharp dissection. Sims

speculum inserted with urinary bladder and uterus. Vesico Uterine fold of peritoneum was identified and it was cut with knife.

Instead of ligating from below we started from above, First clamp was for counrual structures - Round ligament, utero ovarian ligamnet, Fallopien Tube with the help of Heaney's stitch, bilaterally clamped, cut and ligated with vicryl 2-0. The second clamp for Bilateral Uterosacral ligament, bilaterally clamped, cut and ligated. The third clamp was for bilateral Mackernrod's ligament, bilaterally clamped, cut, ligated. The fourth clamp was for uterine artery clamped, cut and ligated bilaterally. Complete hemostasis was confirmed.

For the Cystocoele repair – Urinary Bladder Bulge was identified, interrupted stitches were taken on the vesical fascia and the last stitch was passed from vesical fascia, posterior peritoneum of pouch of doughlas and vesical fascia using chromic catgut 2-0. Vaginal Fascia was again sutured with Bodlock stitches by Vicryl 2-0.

In this way Cystocoele repair was done in two layers with vesical and vaginal fascia.

Redundant anterior vaginal wall cut, Vagina closed in the midline, closed with continuous stitch. Vagina was sutured with continuous inter locking stitches with Vicryl 1-0.

For correction of rectal mucosal prolapse, the prolapsed portion is repositied back. Upper Margin of skin tag of perineum was cut and it was converted into third degree perineal tear.

With the help of two Allis forceps, Vaginal Mucus Membrane was cut at 3 o'clock, 5 o'clock, 1 o'clock in the midline, **Vaginal:** Rectal mucus membrane was cut. Rectal Mucosa was held with two Allis Forceps. Space between the two was dissected with the help of sharp dissection with the help of curved fine dissecting scissor.

Apex of rectal tear identified by doing a per rectal examination, continuous Vicryl 2-0 used for rectal mucus membrane. In this way, anterior rectal wall and anterior wall of anal canal created. Sphincter Ani on right and left side identified and held with Allis forceps. Vicryl 2-0 was used to suture two sphincter anii and anterior wall of rectum. Now levator ani of both the sides was held between lateral vaginal wall and rectum- two stitches were taken, one above and one below levator anii. Redundant posterior vaginal wall was cut, triangular Incision was closed with continuous Vicryl 1-0. Pernieal skin was closed with vertical mattress Vicryl 3-0. At the end, betadiene pack was kept in the vagina and glycerine pack in the rectum. Strapping of buttocks was done.

Post-Operative Course

The patient was managed on broad spectrum antibiotics –third generation cephalosporins, metronidazole with aminoglycoside and analgesics. On second post-operative day betadiene pack was removed and no active bleeding and prolapsed was present. Upon peristalsis she was started on liquid diet first followed by soft diet with increasing dose of stool softeners as and when needed.

Catheter was kept for 24 days and only proper continence of urine and stool patient was discharged.



Fig. 2: Post-operative

Discussion

Pelvic organ prolapse can be staged by two methods.

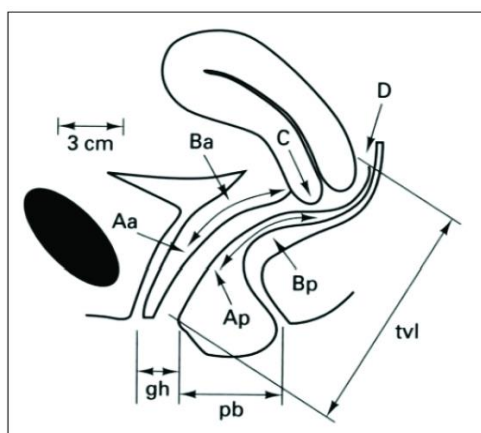


Fig. 3: Pop Q classification system

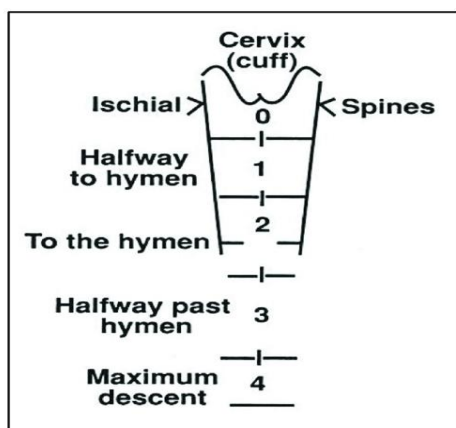


Fig. 4: Baden walker classification system

According to the POP –Q system hymen acts as a fixed point of reference. There are six defined points of measurement –Aa, Ba, C, D, Ap, Bp and there are three landmarks: GH, TVL, PB. Each of which is measured in centimeters below or distal to hymen and distal to hymen (positive number) with plane of hymen being defined as zero.⁷ The terminology avoids labelling cystocele or

rectocele to the prolapsing part of the vagina, acknowledging that the actual organs above the prolapse cannot be determined frequently by physical examination.

In Baden Walker Scoring system, Vagina is divided through a coronal plane, tridimensional anatomy can be simplified by two dimensions only. The numbers represent baden walker vaginal profile sites. The examination is performed by patient straining so that maximum descent is attained. Strength of levator ani is graded out of 4.⁸⁻¹⁰

Both of these can help us clear out and visualize the anatomy of prolapse before surgery.

The only thing that has to bore in mind as obstetricians is avoid operative vaginal delivery especially forceps delivery and counsel patients for post partum pelvic floor muscle exercises. (Unclear status, No Harm) and Perineal Massage. (Unclear status, No Harm). Episiotomy preferable rather than perineal tear. Epidural Analgesia (possible protection) with a strict Avoidance of forceps (risk reduction by 20 to 40%) Avoidance of vaginal delivery (risk reduction by 60-80%).

Teaching Points: To manage such a rare case and do the best instilled for the patient.

Conflict of Interest: None.

References

1. Pelvic organ prolapse –A review from the Royal Australian College of General Practitioners 2015.
2. Oslen AI, Smith VJ, Bergstrom JO, Colling JC, Clark AL. Epidemiology of surgically managed pelvic organ prolapse and urinary incontinence. *Obstet Gynecol* 1997;89:501-506.
3. Svabik K., Shek K, Dietz H. how much does levator hiatus have to stretch during childbirth ? *Br J Obstet Gynaecol* 2009;116:1657-1662.
4. Barber MD. Symptoms and outcome measures of pelvic organ prolapse. *Clin Obstet Gynecol* 2005;48:648-661.
5. Gerges B, Kamisan Atan I, Shek KL, Dietz HP. How to determine ‘Ballooning’ of the levator hiatus on clinical examination: A retrospective observational study. *Int Urogynecol J* 2013;24:1933-1937.
6. Green K, Caudwell Hall, Kamistan Atan I, Shek KL, Langer S, Dietz HP. perineal and vaginal tears are markers for occult levator ani trauma. *Neurorol Urodyn* 2014;33:858-859.
7. Laddad MM, Kshirsagar NS, Nagre N. Rare Case of Huge rectal and uterovaginal prolapse. *Int J Reprod Contracept Obstet Gynecol* 2013;2:237-239.
8. Dhama V, Chaudhary R, Singh S, Singh M. Evaluation of pelvic organ prolapse by standardized pop q system for vaginal hystrectomy. *Int J Reprod Contracept Obstet Gynecol* 2017;6:2584-2588.
9. Bump RC, Mattiasson A, Bo K. The standardization of terminology of female pelvic organ prolapse and pelvic floor dysfunction. *Am J Obstet Gynecol* 1996;175(1):10-17.
10. Baden WF, Walker TA, Lindsday HJ. The Vaginal Profile. *Tex Med J* 1968;64(5):56-58.

How to cite this article: Mehta D, Pawani C, Pandya N. A rare case of procidentia with rectal prolapse: A revolutionary change needed in the delivery practices in rural India. *Indian J Obstet Gynecol Res* 2019;6(1):116-118.