

## Intra-cardiac feticide injection for cervical ectopic pregnancy less than 10 weeks of gestation: A case report and review of literature

Ayman Shehata Dawood<sup>1\*</sup>, Manal Abdraoof Farahat<sup>2</sup>

<sup>1,2</sup>Lecturer, Dept. of Obstetrics and Gynaecology, Tanta University, Tanta, Egypt

\*Corresponding Author: Ayman Shehata Dawood

Email: [ayman.dawood@med.tanta.edu.eg](mailto:ayman.dawood@med.tanta.edu.eg)

Received: 4<sup>th</sup> April, 2019

Accepted: 6<sup>th</sup> May, 2019

### Abstract

**Objective:** To report a case of cervical ectopic managed by intra-cardiac injection of potassium chloride to terminate pregnancy.

**Design:** Case Report.

**Patient:** A 24-year-old G2P1+0, presented with vaginal bleeding. Cervical pregnancy (7 weeks+4 days) was diagnosed by transvaginal ultrasound.

**Intervention:** Intra-cardiac injection of (KCL) was done plus intra-amniotic injection of methotrexate under ultrasound guidance.

**Outcomes:** Safe pregnancy termination and uterine preservation.

**Results:** Pregnancy was terminated successfully, without complications or side effects.

**Conclusion:** Intra-cardiac injection of KCL appears to be an effective and safe method in termination of cervical ectopic pregnancy less than 10 weeks.

**Keywords:** Cervical ectopic, Intra-cardiac feticide, Potassium Chloride, Methotrexate.

### Introduction

Cervical ectopic pregnancy is a very rare but serious condition owing to the complications related to both condition and its management options. The condition has an incidence between 1:2500 to 1:18000 of pregnancies and less than 1% of ectopic pregnancies.<sup>1</sup>

Catastrophic complications occur during any attempt to disturb pregnancy by dilatation and curettage leading to severe uncontrollable hemorrhage ending in hysterectomy.<sup>2</sup>

Management was designed to prevent catastrophic complications depending on gestational age, desire to preserve fertility, and hemodynamic stability. Management options include local or systemic methotrexate administration, ligation of descending cervical branches of uterine arteries, cerclage and cervical tamponade balloon. None of these methods proved to be superior to others. Hysterectomy is a curative solution saving patient's life, but not suitable for patient who wish future fertility.<sup>3,4</sup>

### Case presentation

A 24 years old patient G2P1+0 presented with amenorrhea for 3 weeks after a period of irregular bleeding. The patient sought medical advice at primary care hospital with pregnancy test yielding positive result. The patient gave history of rheumatoid arthritis controlled by medications where these medications were reviewed and managed according to pregnancy food and drug administration (FDA) drug categories. The patient was advised to take folate supplementations and investigations were requested including CBC, liver and renal functions.

Two weeks later, the patient came back with vaginal spotting, ultrasound was done at the primary care hospital where gestational sac was seen inside the cervical canal and a fetus of 7 weeks+4 days gestation was seen with evident

cardiac pulsation. The patient was referred to a tertiary care Hospital. The first investigation requested after evaluation was  $\beta$ -hCG level where it was 85829 IU/ml.

Higher consultation of 3 professors was done where they decided to terminate pregnancy in a safe manner with preservation of the uterus as the patient has only one female child. Under general anesthesia, 2 ml of potassium chloride 15% solution was injected into fetal heart under guidance of transvaginal ultrasonography then aspiration of amniotic fluid then instillation of methotrexate (1mg/kg) into gestational sac. The injected dose was 68 mg according to patient's weight. The needle used was that of oocytes retrieval in intra-cytoplasmic sperm injection (ICSI) (16-Gauge, single lumen needle). The procedure was illustrated in (Fig.1-4).

Follow up of the patient was done for 3 days at Tanta University Hospital to check any major bleeding and to check  $\beta$ -hCG level before discharge. No major bleeding was reported and  $\beta$ -hCG level at discharge was 77065 IU/ml. The patient was discharged and instructed about danger signs and to come again if any of these signs are present. The return visits were scheduled to be weekly for 4 weeks with new  $\beta$ -hCG level to be done at each visit then every 2 weeks till the  $\beta$ -hCG level become negative. Fortunately, no danger signs occurred and  $\beta$ -hCG level was decreasing steadily. The gestational sac was found collapsed and  $\beta$ -hCG level was 54487 IU/ml after 2 weeks of treatment, then the titer became 36549 IU/ml after another 2 weeks. The level became 5 IU/ml after another 5 weeks.

The patient received combined oral contraceptives for 3 months later and is doing well. There were no reported complications except for anemia (Hb=8.2 gm/dl) managed by I.M iron injection for one month.

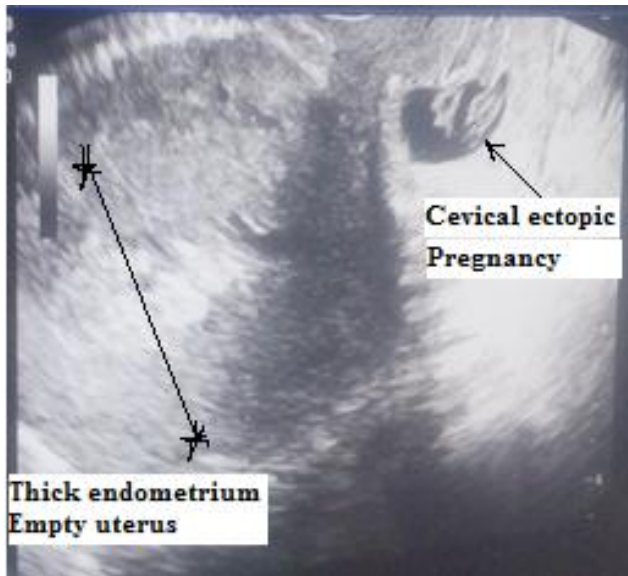


Fig. 1: Intact cervical ectopic pregnancy

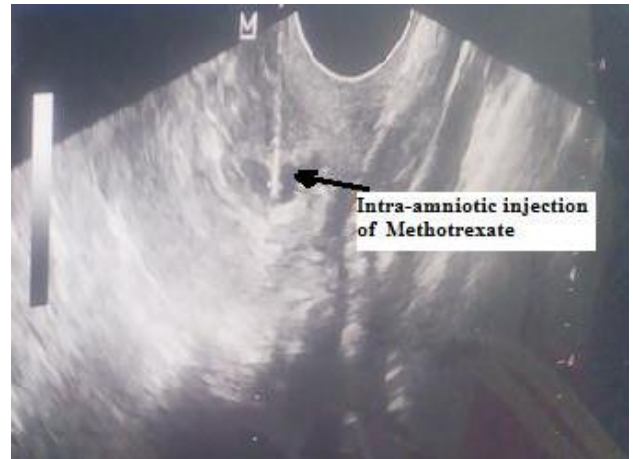

Fig. 4: Instillation of local methotrexate

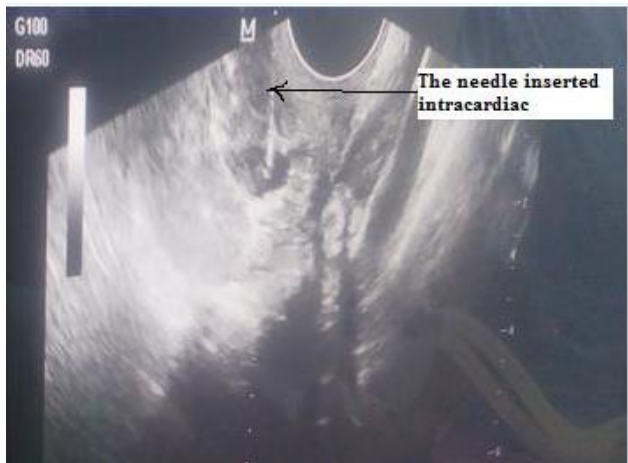


Fig. 2: Intra-cardiac injection of KCL into fetal heart using oocyte retrieval needle

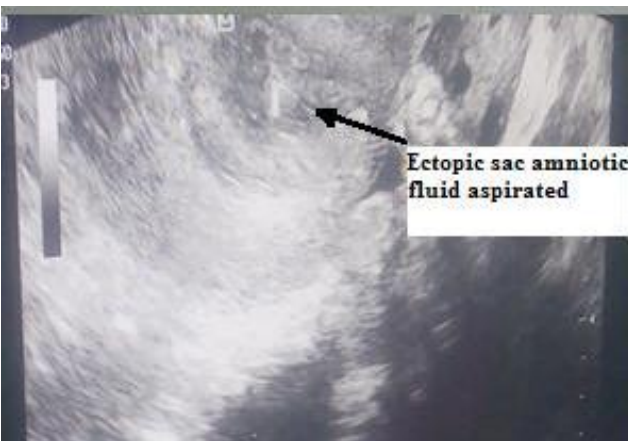

Fig. 3: Aspiration of amniotic fluid

**Discussion**

Cervical ectopic is a very critical obstetric complication if not diagnosed or poorly managed. Severe bleeding may occur jeopardizing patient's life and may necessitate hysterectomy to rescue patient's life.<sup>5</sup>

Many options of treatment were tried in management of cervical ectopic pregnancy but no one proved to be superior to others. Choice of the best treatment modality depends on gestational age, hemodynamic stability and desire of future fertility.<sup>6</sup> Uludag et al (2017) retrospectively reviewed all cases of cervical ectopic pregnancy managed conservatively either by local and systemic methotrexate in the period from 2010 to 2015. They found that both systemic and local methotrexate was successful regarding maternal morbidity and reproductive function.<sup>7</sup>

In this case report, intra-cardiac injection of KCL 15% solution caused cessation of cardiac pulsation plus instillation of local methotrexate caused destruction of trophoblastic tissue evidenced by steady drop in  $\beta$ -hCG level during the follow up period. This modality of treatment is recommended for cervical ectopic less than 10 weeks as it was not associated with any major complications or any danger signs.

**Literature Review**

Published studies in the last 10 years were reviewed on Google Scholar, Pubmed, Medline, Researchgate and Clinical key in the period from January, 1, 2009 to October, 31, 2018.

The included studies were that written in English, full text, and addressing local management of cervical ectopic less than 10 weeks, in the last 10 years. The studies found were either retrospective, case reports or case series. The reported studies were shown in table 1.

**Table 1:** Relevant studies in the literature review

Author	year	Patient age	Gestational age	β-HCG prior to treatment	Method used for management	Complications	Duration till negative β-HCG
Palshetkar [15]	2009	32	5-6 weeks	502 IU/ml	Systemic MTX then Local MTX	Vaginal bleeding +UAE	3 months
Moon [12]	2010	41	6wks+4 days	24,076 mIU/mL	Local MTX	NM	3weeks+3 days
Pereira [13]	2013	33	NM	NM	Local KCL, systemic MTX, and UAE	Acute hemorrhage	3 months
Zakaria [14]	2011	35	7 weeks	130,464 mIU/mL	Systemic MXT with or without UAE and local (KCL).	NM	NM
Begum [8]	2012	26	6 weeks	12,785mIU/ml	Systemic MTX+Misoprostol	Severe hemorrhage	1 month
Šijanović [10]	2014	31	5 weeks	16553.5 IU/L,	Local MTX+hysteroscopy	Remanaents	40 days
Murji [11]	2015	34	7 weeks	11 300 IU/L	Systemic MTX	Vaginal bleeding	26 days
Prameela [2]	2016	25	8 weeks	85860 mIU/ml	MTX+ Mefiprestone +Curettage+Balloon tamponade	NM	NM
Sardo [9]	2017	36	5wks+5days	19352 mUI/mL.	systemic and local MTX therapy combined with hysteroscopic resection.	NM	1 month
Uludag [7]	2017	23-40	6wks-8wks+2days	29 706.9 ± 19 695.2mIU/ml	Local and systemic MTX	oral ulceration in systemic MTX and severe hemorrhage in local MTX	8.8 ± 3.6 weeks

WK: week, MXT: methotrexate, KCL: potassium chloride, UAE: uterine artery embolization, NM: not mentioned,

The age of cases ranges from 25-41 years, the gestational age ranged from 5 weeks to 8 weeks+2 days. The β-HCG prior to treatment was variable ranged from 512 mIU/ml to 130,464 mIU/mL. The methods used for termination were local injection of methotrexate or KCL with or without systemic methotrexate and other methods to control bleeding like uterine artery embolization cervical tamponade and hysteroscopic resection of gestational remnants. The main reported complication is vaginal bleeding managed by additional measures mentioned before. The time needed till negative β-HCG ranged from 3weeks+3 days to 3 months.

### Conclusions

Intra-cardiac injection of KCL into fetal heart plus instillation of intra-amniotic methotrexate leads to destruction of trophoblastic tissue evidenced by steady drop of β-HCG levels. This method was found to be safe and not associated by any major complication and effective in preservation of the uterus.

### Acknowledgement

All thanks go to Professor Hesham A. Salem for his great help and assistance in operating this case and for his continuous support and guidance.

**Conflict of Interest:** None.

### References

1. Youssef HM, Emam M, Zayed A. "Conservative management of 14 weeks cervical ectopic pregnancy: Case report" *Middle East Fertil Soc J* 2016;21:4:281-4
2. Prameela RC, Dev SV. "Cervical ectopic pregnancy: 10 year experience at tertiary care hospital and current literature review" *Int J Reprod Contracept Obstet Gynecol* 2016;5:734-42.
3. Lin EP, Bhalt S, Dogra VS. "Diagnostic clues to ectopic pregnancy". *Radiographics* 2008;28(6):1661-75.
4. Friederike Hoellen, Klaus Diedrich, Christine Dittmer, Katharina Kelling & Michael K Bohlmann. "Therapeutic management of cervical ectopic pregnancy". *Expert Rev Obstet Gynecol* 2011;6:1:85-92. DOI: 10.1586/eog.10.67
5. Chang HC, Chiu TH, Lo LM. "Early Cervical Ectopic Pregnancy: A Case Report and Review of the Literature". *J Med Ultrasound* 2014;22(2):117-9.
6. Samal SK, Rathod S. "Cervical ectopic pregnancy". *J Nat Sci Biol Med* 2015;6(1):257.
7. Uludag SZ, Kutuk MS, Aygen EM, Sahin Y. "Conservative management of cervical ectopic pregnancy: Single-center experience". *J Obstet Gynaecol Res* 2017;43(8):1299-1304. doi: 10.1111/jog.13362.
8. Begum J, Begum SN, Ara R, Nargis SF. "A Case of Cervical Ectopic Pregnancy". *Bangladesh J Obstet Gynaecol* 2012;27(1):31-5.
9. Sardo AD, da Cunha Vieira M, Laganà AS, Chiofalo B, Vitale SG, Scala M, De Falco M, Nappi C, Catena U, Bifulco G.

- "Combined systemic and hysteroscopic intra-amniotic injection of methotrexate associated with hysteroscopic resection for cervical pregnancy: A cutting-edge approach for an uncommon condition". *Eurasian J Med* 2017;49(1):66.
10. Šijanović S, Vidosavljević D, Topolovec Z, Milostić-Srb A, Mrčela M. "Management of cervical ectopic pregnancy after unsuccessful methotrexate treatment". *Iranian J Reprod Med* 2014;12(4):285.
  11. Murji A, Garbedian K, Thomas J, Cruickshank B. "Conservative management of cervical ectopic pregnancy". *J Obstet Gynaecol Can* 2015;37:11:1016-20.
  12. Moon HS, Hyun JH, Kim KS, Kim HJ, Moon SE, Koo JS. "Use of Tuohy needle for intraamniotic methotrexate injection through the cervical canal in a cervical pregnancy after failure of systemic methotrexate treatment". *Am J Obstet Gynecol* 2010;202(5):e4-6.
  13. Pereira N, Grias I, Foster SE, Della Badia CR. "Acute hemorrhage related to a residual cervical pregnancy: management with curettage, tamponade, and cerclage". *J Minim Invasive Gynecol* 2013;20(6):907-11.
  14. Zakaria MA, Abdallah ME, Shavell VI, Berman JM, Diamond MP, Kmak DC et al. "Conservative management of cervical ectopic pregnancy: utility of uterine artery embolization". *Fertil Steril* 2011;95(3):872-6.
  15. Palshetkar N, Pai H, Bansal B. "Cervical Ectopic Pregnancy". *J South Asian Federation Obstet Gynecol* 2009;1(1):40-1.

**How to cite this article:** Dawood AS, Farahat MA, Intra-cardiac feticide injection for cervical ectopic pregnancy less than 10 weeks of gestation: A case report and review of literature *Indian J Obstet Gynecol Res* 2019;6(2):233-236.