



## Case Report

# Isolated levocardia- a rare fetal anomaly with successful pregnancy outcome

Debasree Gangopadhyay<sup>1,\*</sup>, Kusagrathi Ghosh<sup>2</sup>, Kamal Oswal<sup>3</sup>

<sup>1</sup>Dept. of Pediatric Cardiology, Rabindranath Tagore International Institute of Cardiac Sciences, Kolkata, India

<sup>2</sup>Dept. of Obstetrics and Gynaecology, VIMS, Kolkata, India

<sup>3</sup>Dept. of Radiology, VIMS, Kolkata, India

## ARTICLE INFO

### Article history:

Received 16-05-2019

Accepted 31-05-2019

Available online 12-09-2019

### Keywords:

Isolated levocardia

## ABSTRACT

Situs abnormality in fetus is rare. Most of the time an abnormal situs is associated with a structural cardiac abnormality and abnormal arrangement of lungs and abdominal viscera. Cardiac situs almost always correlates with visceral situs. Here we report a fetus with reversed abdominal situs in presence of normal cardiac situs, connection and function with successful delivery at term. This is first report of such anomaly in fetus from India.

© 2019 Published by Innovative Publication.

## 1. Introduction

Situs refers to sidedness of the unpaired organs in the body. In solitus situation the stomach and spleen remains on the left side while the liver is on the right side. In situs inversus, the arrangement of the abdominal organs are just reverse of situs solitus. Atrial situs almost always follows visceral situs. We report a case of visceral situs inversus with levocardia with normal atrial situs and a completely normal heart in a fetus which was confirmed post-natally after an uneventful delivery.

## 2. Materials and Methods

Our patient, a 28 year old 2<sup>nd</sup> gravida lady was referred for fetal echocardiogram with a 17.5 week old fetus with suspected situs abnormality. Her previous pregnancy ended in a spontaneous abortion in the first trimester. The lady was otherwise healthy without any known medical problems. Anomaly scan in the current fetus was normal for organ survey except for the right sided stomach and spleen and left sided liver.

\* Corresponding author.

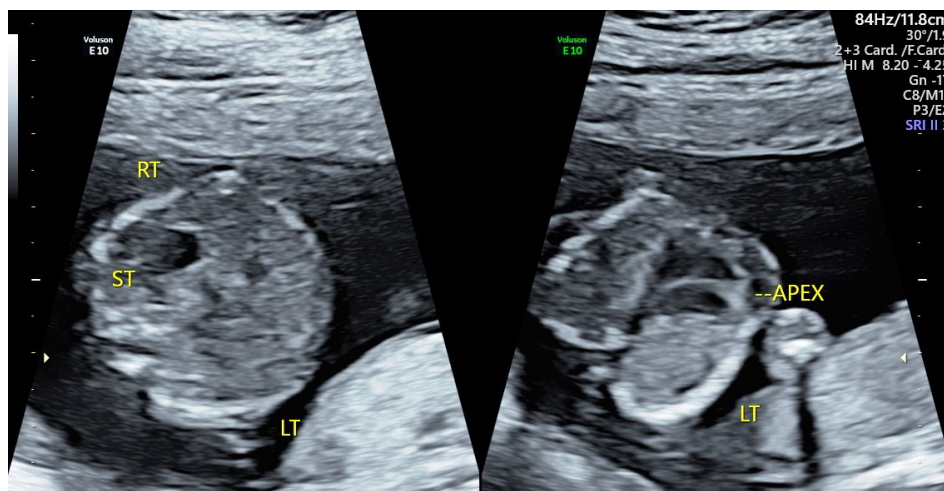
E-mail address: [debasreeganguly23@gmail.com](mailto:debasreeganguly23@gmail.com) (D. Gangopadhyay).

A detailed study of the fetal heart revealed levocardia with cardiac apex pointing to the left while the stomach bubble was on the right side thus the stomach and apex were away from each other. There was a reversed relationship of the abdominal aorta and inferior vena cava on transverse abdominal section. The cardiac structures had normal formation with normal ventricular looping and normal veno-atrial and ventriculo-arterial connections.

The lady underwent amniocentesis. Fetal karyotype, CGH microarray, quantiferon PCR analysis and ciliopathy genetic panel were checked from the amniotic fluid sample and was found negative. With reassurance from the treating obstetrician, the parents decided to continue pregnancy and a beautiful baby girl was born at 37 weeks by caesarean section.

## 3. Result

The perinatal period was uneventful. Post natal cardiac and abdominal ultrasound revealed visceral situs inversus, left sided liver, right sided normally developed spleen and stomach, structurally normal heart with a small midmuscular ventricular septal defect (VSD) of no hemodynamic significance.



**Fig. 1:** Stomach bubble and cardiac apex pointing away from each other

#### 4. Discussion

Levocardia is said to be present when majority of the heart is in the left chest with cardiac apex pointing to the left. Isolated levocardia (IL) is a condition when the cardiac apex is pointing to the left but the visceral situs is either ambiguous or inversus. IL is very rare and is frequently associated with complex congenital heart disease (CHD) with either asplenia or polysplenia.<sup>1</sup>

Situs inversus with levocardia has an incidence of 1 in 22,000 in the general population and accounts for 0.4-1.2% of all individuals with CHD. Prognosis of IL is poor because of its association with complex CHD. Only 5-13% survive for more than five years.<sup>2</sup> Harris and Rainey, in an extensive review of English literature upto 1965, collected 160 cases of IL with only 9 having a normal heart.<sup>3</sup> Further 2 cases of IL with normal circulation were reported by Chacko et al from Vellore, India with one patient having mild pulmonary stenosis and another completely normal heart.<sup>4</sup>

All available information on isolated levocardia is derived from older children or adults where the diagnosis was made by the clinical presentation due to the cardiac defect or bowel obstruction. There are only few reports of isolated levocardia diagnosed in fetal life.<sup>5-7</sup> Ours is the first report of isolated levocardia diagnosed in a 17 weeks old fetus from India.

The cause of IL remains unknown. There is a mirror image reversal of internal organs. Often it is associated with structural heart defects, mostly cyanotic heart disease or rhythm abnormalities. Splenic malformations (absent spleen, underdeveloped or multiple splenules) and malrotation of gut are other known associations.<sup>2</sup>

No pathogenic gene mutations have been identified. In about 1.6% of patients with lateralization defect, activin receptor IIB gene mutation has been found. Maternal diabetes is also described in lateralization defects.<sup>7</sup> Primary

ciliary dyskinesia (PCD) can be associated with situs inversus. Several gene mutation is known to be associated with PCD. Our patient did not have diabetes and ciliopathy gene panel done from amniocentesis sample was negative.

Anomaly scan in our patient suggested visceral situs inversus. Targeted cardiac scan revealed normal cardiac development. The findings were confirmed post-natally by abdominal and cardiac ultrasound. The baby had normally developed spleen on the right side, normal kidneys and left sided inferior vena cava (IVC) draining into the right atrium. There was one small mid-muscular VSD in an otherwise normal heart.

In the previous fetal series of 3 fetuses with IL, all of them had splenic abnormality.<sup>6</sup> 2 of the three fetuses had polysplenia and 1 had asplenia. IVC was interrupted in all but one baby with polysplenia. None of the fetuses had chromosomal abnormalities on amniocentesis or thoracic isomerism. Our patient was unique in that, she had IL with normal circulation with normal splenic development.

IL can be associated with bowel obstruction in neonate or infant due to peritoneal band, intraluminal web or rarely by aberrant vessel crossing the duodenum. Volvulus of gut can also be rarely present and can cause life threatening bowel obstruction in future.<sup>8</sup> In previously published fetal reports of IL, it was associated with previously malrotation of gut in one neonate. No important cardiac abnormalities were described in the fetal reports<sup>5-7</sup> except for one baby which had self-correcting fetal bradycardia.<sup>7</sup> On the contrary, older children with IL are often identified due to complex cardiac disease or bowel obstruction. It can be assumed that IL fetuses with more severe type of cardiac abnormalities undergo spontaneous abortion. Once IL is identified on prenatal screening a detailed documentation of cardiac anatomy and abdominal organs are important. Solomon et al and Katsuya et al<sup>5,7</sup> have demonstrate the role of fetal magnetic resonance imaging (MRI) as an useful

tool for accurate identification of the fetal abdominal organ disposition. However fetal MRI being a high end and costly imaging with limited availability, detailed fetal ultrasound study should be aimed.

Based on our current knowledge, prospective parents of fetuses with a diagnosis of IL should be guided appropriately after a thorough imaging of the fetus. After birth, these babies should have cardiac and abdominal ultrasound. Any suspicion of intestinal obstruction should be further investigated by barium contrast study to rule out intestinal obstruction, another potentially lethal abnormality despite a normal heart.

## 5. Acknowledgement

None

## 6. Source of funding

None.

## 7. Conflict of interest

No conflict of interest

## References

1. Normal and abnormal cardiac position ( situs anomalies) The Ultrasound of Life (online) www. *Shucet IB*;
2. Jo DS, Jung SS, Joo CU. A case of unusual visceral heterotaxy syndrome with isolated levocardia. *Korean Circ J.* 2013;43:705–709.
3. Harris TR, Rainey RL. Ideal isolated levocardia. *Am Heart J.* 1965;70(4):440–448.
4. Chacko KA, Krishnaswami S, Sukumar IP, Cherion G. Isolated Levocardia: Two cases with abdominal situs inversus, thoracic situs solitus and normal circulation. *Am Heart J.* 1983;106:155–159.
5. Solomon LJ, Baumann C, Delezoid AL, Oury JF, Pariente D, et al. PMID ; 2006,.
6. Gindes L, Hegesh J, Barkai G, Jacobson JM, Achiron R. Isolated levocardia prenatal diagnosis, clinical importance and literature review. *J Ultrasound Med.* 2007;26:361–365.
7. Katsuya, Satoko, Yamada, Shigehito, Ukita, et al. Isolated levocardia; Prenatal diagnosis and management. *Cong Anomalies*;49:56–60.
8. Tryfonas GI, Chaidos C, Avtzoglou PP, Ziolutis J, Klokariis A, Papanastasopoulos A. Partial situs inversus: Duodenal obstruction in a neonate with isolated levocardia. *J Pediatr Surg*;27:1584–1586.

## Author biography

**Debasree Gangopadhyay** Consultant

**Kusagradhi Ghosh** Professor

**Kamal Oswal** Professor

**Cite this article:** Gangopadhyay D, Ghosh K, Oswal K. Isolated levocardia- a rare fetal anomaly with successful pregnancy outcome. *Indian J Obstet Gynecol Res* 2019;6(3):396-398.